

*30 Years of*  
**Guided Bone  
Regeneration**

THIRD EDITION

*Edited by*

**Daniel Buser, DDS, Prof em Dr med dent**

**30 Years of Guided Bone Regeneration**  
**Third Edition**

## Library of Congress Cataloging-in-Publication Data

Names: Buser, Daniel, editor.

Title: 30 years of guided bone regeneration / edited by Daniel Buser.

Other titles: Thirty years of guided bone regeneration | 20 years of guided bone regeneration in implant dentistry.

Description: Third edition. | Batavia, IL : Quintessence Publishing Co, Inc, [2021] | Preceded by 20 years of guided bone regeneration in implant dentistry / edited by Daniel Buser. 2nd ed. c2009. | Includes bibliographical references and index. | Summary: "Descriptions of various evidence-based guided bone regeneration techniques to prepare deficient jaws for implant surgery, including biologic rationale and case examples"-- Provided by publisher.

Identifiers: LCCN 2021001778 (print) | LCCN 2021001779 (ebook) | ISBN 9780867158038 (hardcover) | ISBN 9780867159967 (ebook)

Subjects: MESH: Guided Tissue Regeneration, Periodontal | Bone Regeneration | Dental Implantation, Endosseous--methods

Classification: LCC RD123 (print) | LCC RD123 (ebook) | NLM WU 600 | DDC 617.4/710592--dc23

LC record available at <https://lcn.loc.gov/2021001778>

LC ebook record available at <https://lcn.loc.gov/2021001779>

A CIP record for this book is also available from the British Library.

ISBN: 9780867158038



© 2022 Quintessence Publishing Co, Inc

Quintessence Publishing Co, Inc  
411 N Raddant Road  
Batavia, IL 60510  
[www.quintpub.com](http://www.quintpub.com)

5 4 3 2 1

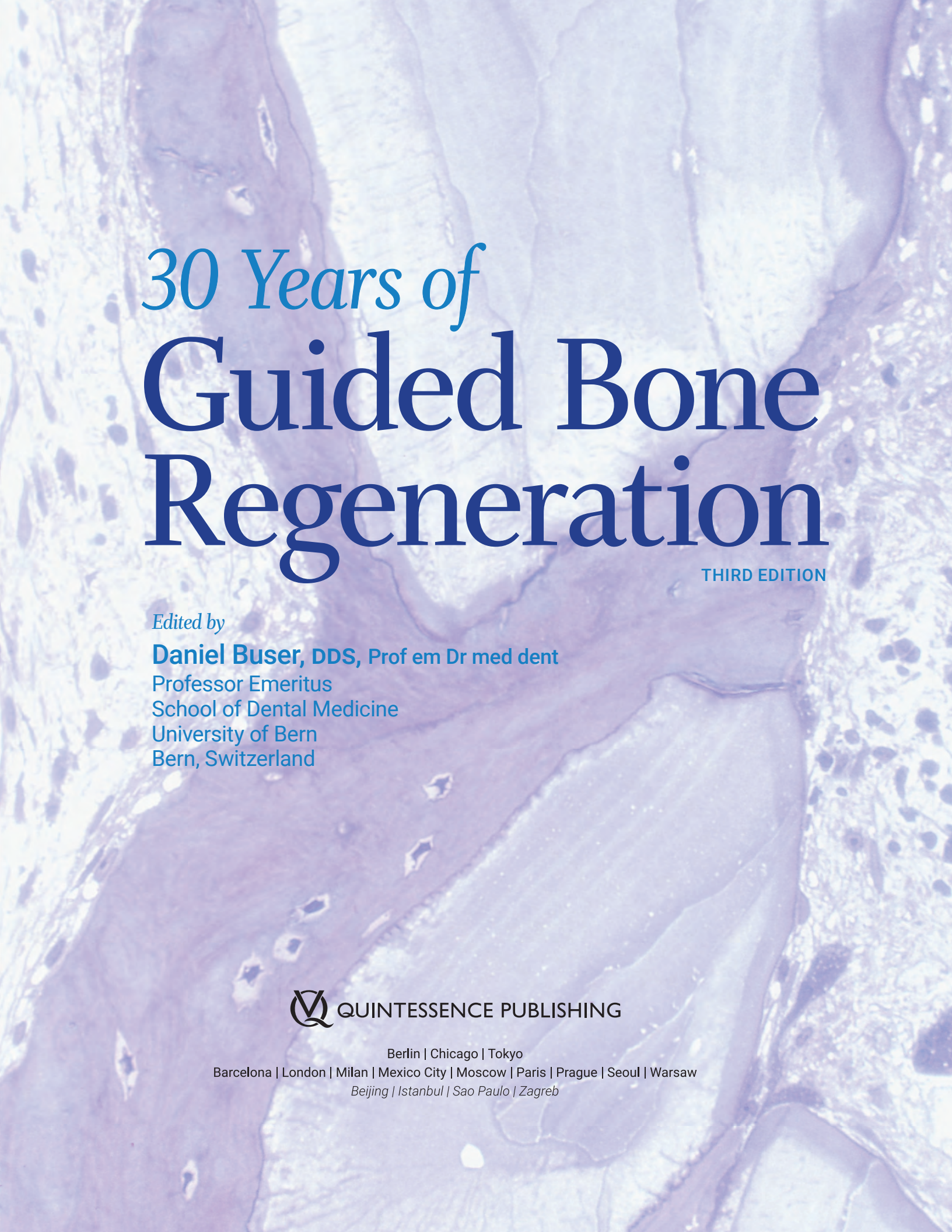
All rights reserved. This book or any part thereof may not be reproduced, stored in a retrieval system, or transmitted in any form or by any means, electronic, mechanical, photocopying, or otherwise, without prior written permission of the publisher.

Editor: Marieke Zaffron

Design: Sue Zubek

Production: Sue Robinson and Sarah Minor

Printed in Croatia

The background of the cover is a high-magnification microscopic image of bone tissue, showing various cellular structures and mineralized areas in shades of purple and blue.

# *30 Years of* **Guided Bone Regeneration**

THIRD EDITION

*Edited by*

**Daniel Buser, DDS, Prof em Dr med dent**

Professor Emeritus

School of Dental Medicine

University of Bern

Bern, Switzerland



QUINTESSENCE PUBLISHING

Berlin | Chicago | Tokyo

Barcelona | London | Milan | Mexico City | Moscow | Paris | Prague | Seoul | Warsaw

*Beijing | Istanbul | Sao Paulo | Zagreb*

# Contents

*Foreword vi*

*Dedication vii*

*Preface viii*

*Contributors x*

## 1 The Development of Guided Bone Regeneration Over the Past 30 Years 1

*Daniel Buser, DDS, Prof em Dr med dent*

## 2 Bone Regeneration in Membrane-Protected Defects 17

*Dieter D. Bosshardt, MSc, PhD | Simon S. Jensen, DDS, Dr odont | Daniel Buser, DDS, Prof em Dr med dent*

## 3 The Biologic Power of Autogenous Bone Grafts 53

*Maria B. Asparuhova, PhD*

## 4 Hard and Soft Tissue Alterations Postextraction 79

*Vivianne Chappuis, DDS, Dr med dent | Mauricio G. Araújo, DDS, MSc, PhD*

*Daniel Buser, DDS, Prof em Dr med dent*

## 5 Anatomical and Surgical Factors Influencing the Outcome of GBR Procedures 93

*Daniel Buser, DDS, Prof em Dr med dent | Alberto Monje, DDS, MS, PhD | Istvan Urban, DMD, MD, PhD*

## 6 Implant Placement Following Extraction in Esthetic Single-Tooth Sites: When Immediate, Early, or Late? 123

*Daniel Buser, DDS, Prof em Dr med dent | Stephen T. Chen, MDS, PhD*

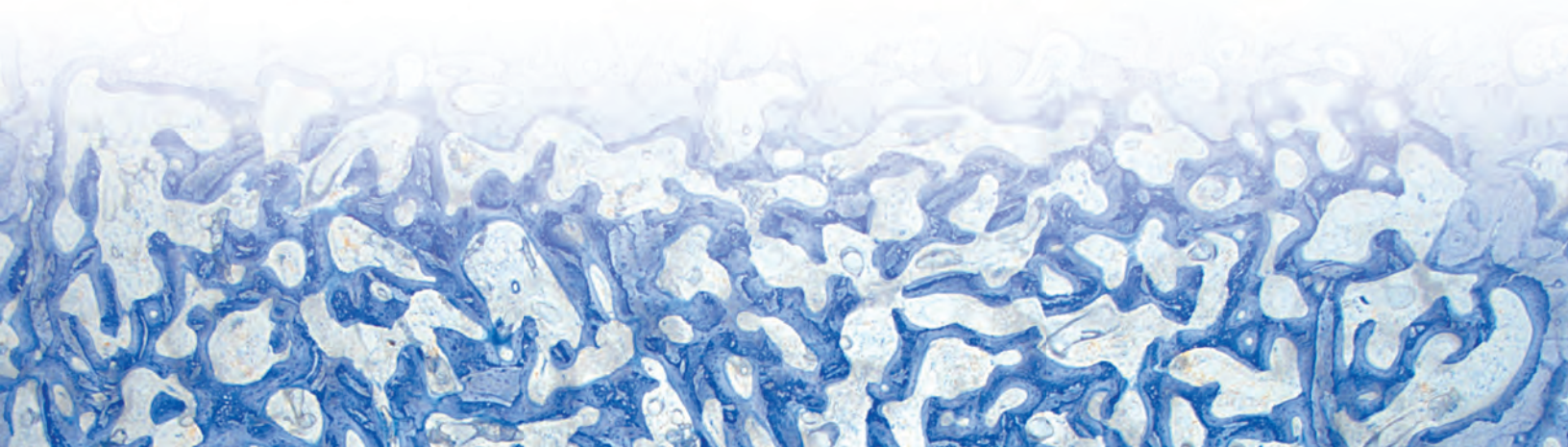
## 7 Immediate Implant Placement with Internal Grafting 143

*Stephen T. Chen, MDS, PhD | Adam Hamilton, BDS, DCD*

## 8 Early Implant Placement with Simultaneous Contour Augmentation Using GBR in the Esthetic Zone 169

*Daniel Buser, DDS, Prof em Dr med dent | Vivianne Chappuis, DDS, Dr med dent*

*Urs C. Belser, DMD, Prof em Dr med dent*



9 GBR Procedures in the Posterior Mandibles of Partially Edentulous Patients 217

*Daniel Buser, DDS, Prof em Dr med dent | Vedrana Braut, DDS, Dr med dent  
Simone F. M. Janner, DDS, PD Dr med dent*

10 Horizontal Ridge Augmentation Using GBR and Autogenous Block Grafts 253

*Vivianne Chappuis, DDS, Dr med dent | Thomas von Arx, DDS, Prof Dr med dent  
Daniel Buser, DDS, Prof em Dr med dent*

11 Vertical and Horizontal Ridge Augmentation Using GBR: The Sausage Technique 273

*Istvan Urban, DMD, MD, PhD | Daniel Buser, DDS, Prof em Dr med dent*

12 Hard and Soft Tissue Augmentation in Defect Sites in the Esthetic Zone 287

*Sascha A. Jovanovic, DDS, MS*

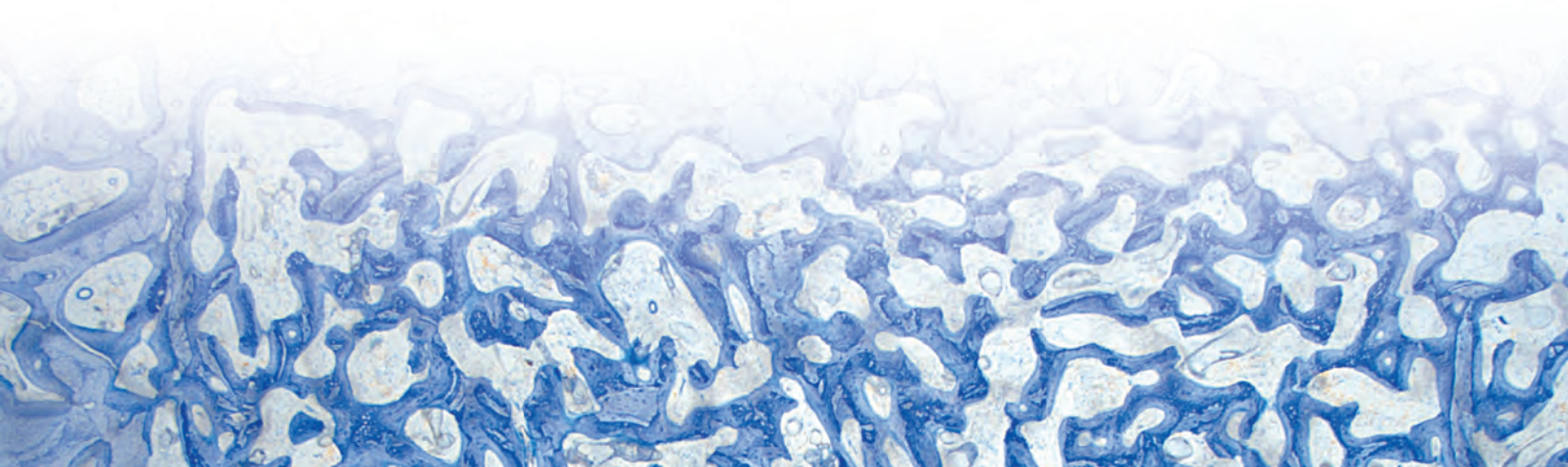
13 GBR for Regenerating Bone Defects Caused by Peri-Implantitis 301

*Frank Schwarz, Prof Dr med dent | Ausra Ramanauskaite, DDS, Dr med dent, PhD*

14 Prevention and Management of Complications in GBR 315

*Isabella Rocchietta, DDS, MSc | Federico Moreno, Lic Odont, M Clin Dent  
Francesco D'Aiuto, DMD, M Clin Dent, PhD*

*Index 333*



---

# Foreword

**T**here have already been three decades of scientific documentation and successful clinical experience in the field of GBR—a truly impressive accomplishment! In this third edition of an already well-established textbook, authored and edited under the judicious leadership of Professor Danny Buser, a carefully selected international panel of experts has updated and shed light from all relevant angles on one of the most significant recent achievements of contemporary dental medicine. The text not only surveys 30 years of progress made; it also comprehensively defines the current state of the art in GBR and its tremendous impact, namely on implant dentistry. Clinical protocols aimed at reducing overall treatment complexity and time, as well as diminishing patient morbidity, have been developed and refined during recent years. In addition, based on the remarkable levels of reliability and predictability of GBR, numerous new avenues for clinical application have been opened.

In fact, the knowledge of which techniques and associated biomaterials are recommended today, linked to the indispensable robust scientific documentation, provide the clinician with the basis for

target-oriented clinical decision making in view of the subsequent treatment. This includes the consideration of the practitioner's individual state of education and competence. Namely, the SAC concept—which objectively differentiates straightforward, advanced, and complex cases in relation to the difficulty level of a given clinical situation—is of particular importance and has been strongly promoted by the main author for many years.

The current third edition of a textbook that has twice already previously reached the status of a true standard of reference has clearly outperformed its two predecessor issues. Beyond any doubt, oral surgeons, periodontists, prosthodontists, and general practitioners, as well as dental students, will find all the detailed information relevant to successful implementation of GBR in daily practice, ultimately to the benefit of countless patients.

**Urs C. Belser, DMD, Prof em Dr med dent**

Professor Emeritus  
School of Dental Medicine  
University of Geneva  
Geneva, Switzerland

---

# Dedication

**T**his textbook is dedicated to Robert K. Schenk, Prof Dr med, who was Professor of Anatomy at the University of Bern, Switzerland. He was a world-renowned scientist in the field of bone physiology and bone healing. His instruction on the basics of bone healing was what allowed for the tremendous progress with GBR we made in the 1990s. Dr Schenk's chapter on the basics of bone healing in the first GBR book was a sensation at that time. He was able to illustrate his knowledge with fantastic histologic pictures produced by his lab. Besides his generosity to share his knowledge and wisdom, he was a true friend and mentor.



**Robert K. Schenk, Prof Dr med (1923–2011)**



---

# Preface

The utilization of barrier membranes for the regeneration of bone defects has significantly changed implant dentistry in the past 30 years and clearly expanded the utilization of dental implants in patients. This principle is called guided bone regeneration (GBR or GBR technique), and was first described in 1959 by Hurley and colleagues for the treatment of experimental spinal fusion. In the 1960s, the research teams of Bassett and Boyne tested Millipore filters for the healing of cortical defects in long bones and osseous facial reconstruction, respectively. The authors utilized these filters to establish a suitable environment for osteogenesis by excluding fibrous connective tissue cells from bone defects. However, these studies did not lead to a clinical application of barrier membranes in patients at that time.

The clinical potential of barrier membranes was picked up in the early 1980s in the field of periodontology by the research team of Nyman and Karring, who systematically examined barrier membranes for periodontal regeneration. A few years later, barrier membranes were also tested for the regeneration of bone defects in experimental studies. The first three studies were done in Gothenburg by Dahlin and Nyman. Based on promising results in these studies, clinical testing of barrier membranes began in implant patients in the late 1980s. After 5 years of intensive experimental and clinical work, the first edition of the textbook *Guided Bone Regeneration in Implant Dentistry* was published in 1994, and it received a high interest by readers in the field of implant dentistry. In 2009, the second edition of the GBR book was published with an update of the scientific knowledge and the surgical techniques being utilized after 20 years of a wide clinical application of GBR.

In the past 12 years, the scientific knowledge and the clinical experience have evolved further. During these years, many fine-tuning efforts have been made for the various surgical techniques to improve the regenerative outcomes, or to reduce the surgical invasiveness for patients. Therefore, it was time to make a new effort to once again analyze the scientific basis of the GBR technique and its clinical applications. The result is in your hands, the third edition of the GBR

book, called *30 Years of Guided Bone Regeneration in Implant Dentistry*. This book is again written for the surgical clinician with an interest and experience in implant dentistry.

As an introduction to the topic of the book, chapter 1 discusses the development and fine-tuning phase of the GBR technique over the past 30 years. Chapter 2 covers the biologic basis of bone regeneration and presents a scientific update on bone formation and bone remodeling. The excellent histology utilizing nondecalcified sections is based on more than 30 years of experimental research, and it presents the details of bone regeneration in general and the details of bone formation in membrane-protected defects with bone grafts or bone substitutes in particular. Chapter 3 is completely new and describes the molecular and cellular characteristics of autogenous bone chips, and how they release various growth factors when put in a mixture of blood and physiologic and sterile saline. Chapter 4 is also completely new and describes the hard and soft tissue alterations following tooth extraction. Clinicians need to understand these biologic mechanisms for proper selection of the most suitable treatment option in postextraction implant placement. Chapter 5 is also new and systematically describes the surgical and anatomical factors influencing the regenerative outcome of GBR procedures, including the interesting classifications of defect morphology.

In the clinical section of the book, chapters 6 to 14, clinical procedures associated with different indications of the GBR technique are presented in detail. Each chapter deals with specific indications and describes the criteria for patient selection, the step-by-step surgical procedure, and aspects of post-operative treatment. Emphasis is given to incision technique and flap design; the selection, handling, and placement of barrier membranes; the combination of membranes with autogenous bone grafts and low-substitution bone fillers; and aspects of wound closure. These chapters of the book reflect the immense progress and excellent documentation of GBR in the past 10 to 15 years, and its outstanding importance in daily practice of implant therapy.

---

## *Acknowledgments*

As editor, I cordially thank all authors and coauthors for their great effort and time to realize this textbook. It has been very intensive work during a pandemic crisis, but a satisfying experience to collaborate with colleagues of such international reputation and high quality. Some of them are long-term personal friends, which makes the pleasure even greater. I also want to share that all authors, including myself, agreed to have the authors' royalties entirely paid into the Buser Implant Foundation, a foundation established in August 2019 right after my retirement as Professor and Chairman at the Department of Oral Surgery and Stomatology, University of Bern, after 20 years of service. The foundation's objectives are the promotion of education and research in the field of implant dentistry by providing personal stipends and junior investigator grants to young colleagues of our

profession. The first Buser Foundation Scholarship in Implant Dentistry has been awarded in spring 2021.

I also thank Bernadette Rawyler, who created all the beautiful digital artwork in my chapters. These illustrations have made it much easier to communicate the correct messages and necessary information from the authors to the reader.

Last but not least, I also cordially thank Bryn Grisham and Marieke Zaffron of Quintessence Publishing for their excellent collaboration to realize this book. The quality work and the quality printing of Quintessence was again superb and is highly appreciated. It reflects almost 30 years of close collaboration with Quintessence Publishing, both in Berlin and in Chicago. I thank Horst Wolfgang Haase, Christian W. Haase, as well as Alexander Ammann for this excellent collaboration over so many years, which was based on trust, respect, and friendship.

---

# Contributors

**Mauricio G. Araújo, DDS, MSc, PhD**

Head of the Research Group in Periodontics and  
Implant Dentistry  
Department of Dentistry  
State University of Maringá  
Maringá, Brazil

**Thomas von Arx, DDS, Prof Dr med dent**

Deputy Clinic Director  
Department of Oral Surgery and Stomatology  
School of Dental Medicine  
Faculty of Medicine  
University of Bern  
Bern, Switzerland

**Maria B. Asparuhova, PhD**

Research Group Leader  
Laboratory of Oral Cell Biology  
Dental Research Center  
School of Dental Medicine  
Faculty of Medicine  
University of Bern  
Bern, Switzerland

**Urs C. Belser, DMD, Prof em Dr med dent**

Professor Emeritus  
School of Dental Medicine  
University of Geneva  
Geneva, Switzerland

**Dieter D. Bosshardt, MSc, PhD**

Professor  
Robert K. Schenk Laboratory of Oral Histology  
School of Dental Medicine  
Faculty of Medicine  
University of Bern  
Bern, Switzerland

**Vedrana Braut, DDS, Dr med dent**

Research Collaborator  
Department of Oral Surgery and Stomatology  
School of Dental Medicine  
Faculty of Medicine  
University of Bern  
Bern, Switzerland

Private Practice  
Matulji, Croatia

**Daniel Buser, DDS, Prof em Dr med dent**

Professor Emeritus  
School of Dental Medicine  
University of Bern  
Bern, Switzerland

**Vivianne Chappuis, DDS, Dr med dent**

Professor  
Department of Oral Surgery and Stomatology  
School of Dental Medicine  
Faculty of Medicine  
University of Bern  
Bern, Switzerland

**Stephen T. Chen, MDSc, PhD**

Clinical Associate Professor  
Department of Periodontics  
Melbourne Dental School  
The University of Melbourne  
Parkville, Australia

**Francesco D'Aiuto, DMD, M Clin Dent, PhD**

Professor and Chair  
Periodontology Unit  
Eastman Dental Institute  
University College London  
London, United Kingdom

---

**Adam Hamilton, BDS, DCD**  
Director of the Division of Regenerative and Implant  
Sciences  
Department of Restorative Dentistry and Biomaterials  
Sciences  
School of Dental Medicine  
Harvard University  
Cambridge, Massachusetts

**Simone F. M. Janner, DDS, PD Dr med dent**  
Senior Physician  
Department of Oral Surgery and Stomatology  
School of Dental Medicine  
Faculty of Medicine  
University of Bern  
Bern, Switzerland

**Simon S. Jensen, DDS, Dr odont**  
Professor  
Section of Oral Biology and Immunopathology  
Department of Odontology  
Faculty of Health and Medical Sciences  
University of Copenhagen

Professor  
Department of Oral and Maxillofacial Surgery  
Centre of Head and Orthopedics  
Copenhagen University Hospital  
Copenhagen, Denmark

**Sascha A. Jovanovic, DDS, MS**  
Founder and Academic Chairman  
gIDE Institute  
Los Angeles, California

**Alberto Monje, DDS, MS, PhD**  
Adjunct Clinical Assistant Professor  
Department of Periodontics and Oral Medicine  
School of Dentistry  
University of Michigan  
Ann Arbor, Michigan

Assistant Lecturer  
Department of Periodontology  
Faculty of Dentistry  
Universitat Internacional de Catalunya  
Barcelona, Spain

**Federico Moreno, Lic Odont, M Clin Dent**  
Clinical Lecturer  
Periodontology Unit  
Eastman Dental Institute  
University College London

Private Practice  
London, United Kingdom

**Ausra Ramanauskaite, DDS, Dr med dent, PhD**  
Assistant Professor  
Department of Oral Surgery and Implantology  
Faculty of Medicine  
Goethe University  
Center for Dentistry and Oral Medicine (Carolinum)  
Frankfurt, Germany

**Isabella Rocchietta, DDS, MSc**  
Honorary Senior Research Associate  
Periodontology Unit  
Eastman Dental Institute  
University College London

Private Practice  
London, United Kingdom

**Frank Schwarz, Prof Dr med dent**  
Professor and Chairman  
Department of Oral Surgery and Implantology  
Faculty of Medicine  
Goethe University  
Center for Dentistry and Oral Medicine (Carolinum)  
Frankfurt, Germany

**Istvan Urban, DMD, MD, PhD**  
Assistant Professor  
Department of Restorative Dentistry  
School of Dentistry  
Loma Linda University  
Loma Linda, California

Associate Professor  
Department of Periodontics and Oral Medicine  
School of Dentistry  
University of Michigan  
Ann Arbor, Michigan



# 1

## The Development of Guided Bone Regeneration Over the Past 30 Years

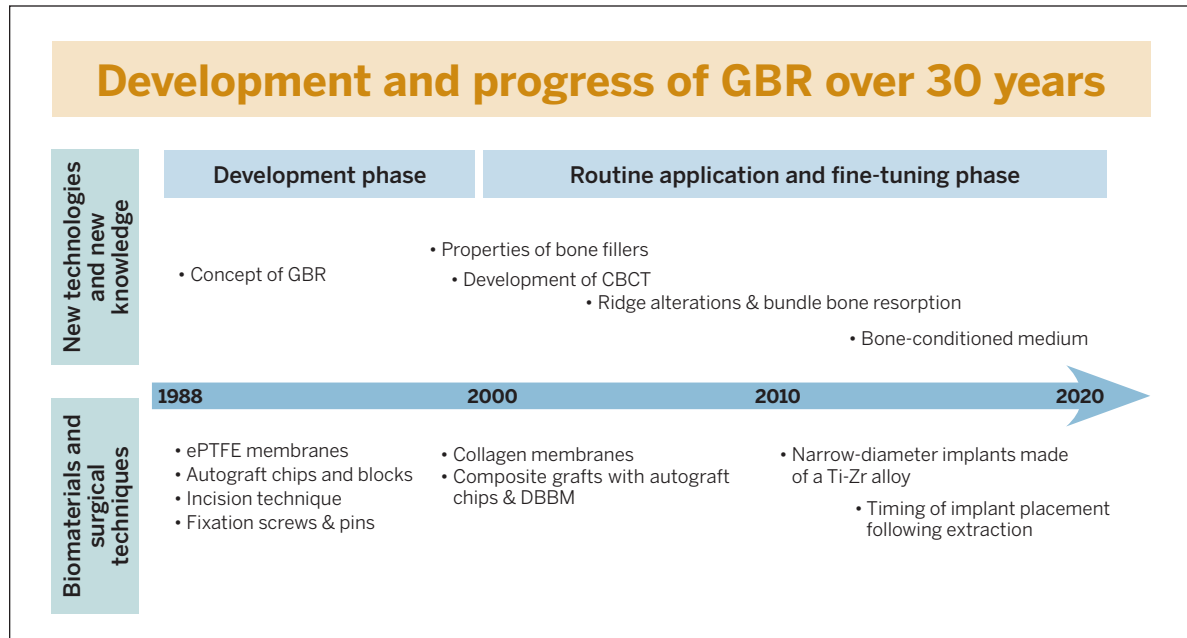
*Daniel Buser, DDS, Prof em Dr med dent*

**M**odern implant dentistry based on the concept of osseointegration recently celebrated its 50th birthday.<sup>1</sup> The tremendous progress made in the rehabilitation of fully and partially edentulous patients is based on fundamental experimental studies performed by two research teams. One team was located in Sweden and headed by Prof P-I Brånemark from the University of Gothenburg; the other was located in Switzerland and headed by Prof André Schroeder from the University of Bern. In the late 1960s and 1970s, the two research groups independently published landmark papers describing the phenomenon of osseointegrated titanium implants.<sup>2-4</sup> An *osseointegrated implant* was characterized by direct apposition of living bone to the implant surface.<sup>5-7</sup>

In the early phase of this development, several prerequisites were identified for osseointegration to be achieved.<sup>2,3</sup> Some of these have been revised over the past 50 years; others are still considered important. In order to achieve osseointegration, the implant must be placed using a low-trauma surgical technique to avoid

overheating the bone during preparation of a precise implant bed, and the implant must be inserted with sufficient primary stability.<sup>5,8</sup> When these clinical guidelines are followed, successful osseointegration will predictably occur for nonsubmerged titanium implants (single-stage procedure) as well as for submerged titanium implants (two-stage procedure), as demonstrated in comparative experimental studies.<sup>9,10</sup>

When clinical testing of osseointegrated implants first began, the majority of treated patients were fully edentulous. Promising results were reported in retrospective studies.<sup>11-13</sup> Encouraged, clinicians increasingly began using osseointegrated implants in partially edentulous patients, and the first reports on this utilization were published in the late 1980s and early 1990s with promising short-term results by various groups.<sup>14-18</sup> As a consequence, single-tooth gaps and distal extension situations have become more and more common indications for implant therapy in daily practice. Today, these practices dominate in many clinical centers.<sup>19-21</sup>



**Fig 1-1** Development of GBR over 30 years since the late 1980s. ePTFE, expanded polytetrafluoroethylene; DBBM, deproteinized bovine bone mineral; Ti-Zr, titanium-zirconium.

One of the most important prerequisites for achieving and maintaining successful osseointegration is the presence of a sufficient volume of healthy bone at the recipient site. This includes not only sufficient bone height to allow the placement of an implant of adequate length, but also a ridge with sufficient crest width. Clinical studies in the 1980s and 1990s showed that osseointegrated implants lacking a buccal bone wall at the time of implant placement had an increased rate of soft tissue complications and/or a compromised long-term prognosis.<sup>22,23</sup> To avoid increased rates of implant complications and failures, these studies suggested that potential implant recipient sites with insufficient bone volume should either be considered local contraindications for implant placement or should be locally augmented with an appropriate surgical procedure to regenerate the local bone deficiency.

During these early decades, several attempts were made to develop new surgical techniques to augment local bone deficiencies in the alveolar ridge in order to overcome these local contraindications for implant therapy. The proposed techniques included vertical ridge augmentation using autogenous block grafts from the iliac crest in extremely atrophic arches,<sup>24,25</sup> sinus floor elevation procedures in the maxilla,<sup>26-28</sup> the application of autogenous onlay grafts for lateral ridge augmentation,<sup>29-31</sup> or split-crest techniques such as alveolar extension plasty.<sup>32-34</sup>

During the same period, in addition to these new surgical techniques, the concept of guided bone regeneration (GBR) with barrier membranes was introduced. Based on case reports and short-term clinical studies, various authors reported first results with this membrane technique for the regeneration of localized bone defects in implant patients.<sup>35-40</sup>

This textbook will provide an update on the biologic basis of the GBR technique and its various clinical applications for implant patients. Clinical experience with GBR in daily practice now spans 30 years. These 30 years can be divided into a development phase and a phase of routine application with extensive efforts to fine-tune the surgical procedure (Fig 1-1). The focus was on improving the surgical technique, expanding the range of applications, improving the predictability for successful outcomes, and reducing morbidity and pain for the patients.

## Development Phase of GBR

The use of barrier membranes for implant patients was certainly triggered by the clinical application of barrier membranes for periodontal regeneration, called *guided tissue regeneration* (GTR). GTR was first developed in the early 1980s by the group led by Nyman et al.<sup>41,42</sup> The initial studies were performed with Millipore filters, which had already been used in experimental studies in the late 1950s and 1960s for the regeneration of bone defects.<sup>43-45</sup> However, these studies had no impact on the development of new surgical techniques to regenerate localized defects in the jaws, because the potential of this membrane application was probably not recognized at that time.

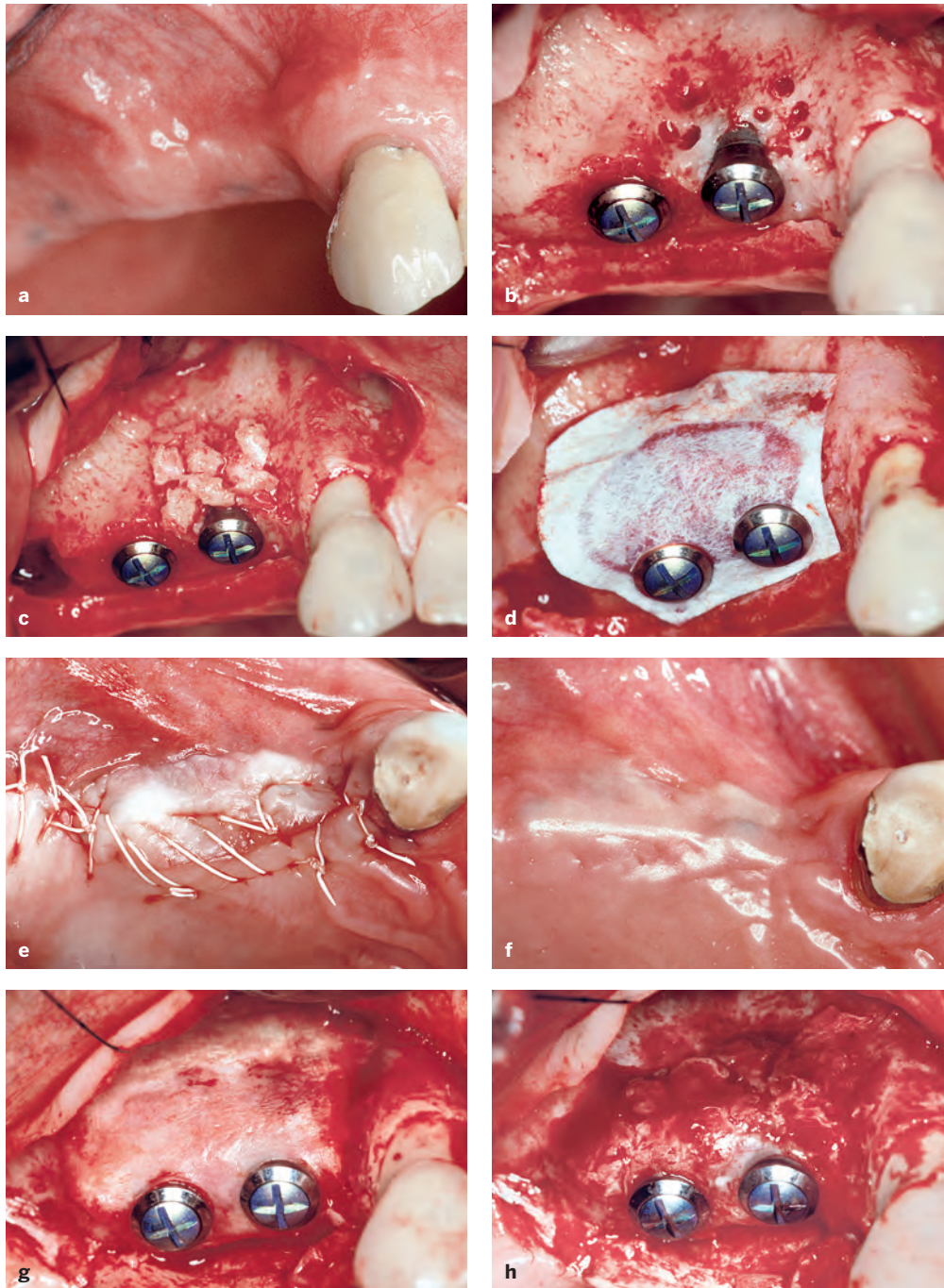
The two papers by Nyman et al.<sup>41,42</sup> in the field of GTR, both of which demonstrated successful treatment outcomes of GTR procedures, were received with great interest and led to increased research activities in the mid to late 1980s.<sup>46-49</sup> These studies were already being performed with expanded polytetrafluoroethylene (ePTFE), which is a bioinert membrane and became the standard membrane for GTR and GBR procedures during the development phase of both techniques. The use of ePTFE membranes for bone regeneration was initiated in the mid 1980s by the group of Dahlin et al, who performed a series of preclinical studies.<sup>50-52</sup> These studies confirmed the concept that the application of an ePTFE membrane established a physical barrier that separated the tissues and cells that could potentially participate in

the wound healing events inside the secluded space. The barrier membrane promoted the proliferation of angiogenic and osteogenic cells from the marrow space into the bone defect without interference by fibroblasts. These events were nicely demonstrated by Schenk et al<sup>53</sup> in a landmark experimental study in foxhounds. The current biologic understanding of wound healing events in membrane-protected bone defects is presented in detail in chapter 2 of this textbook.

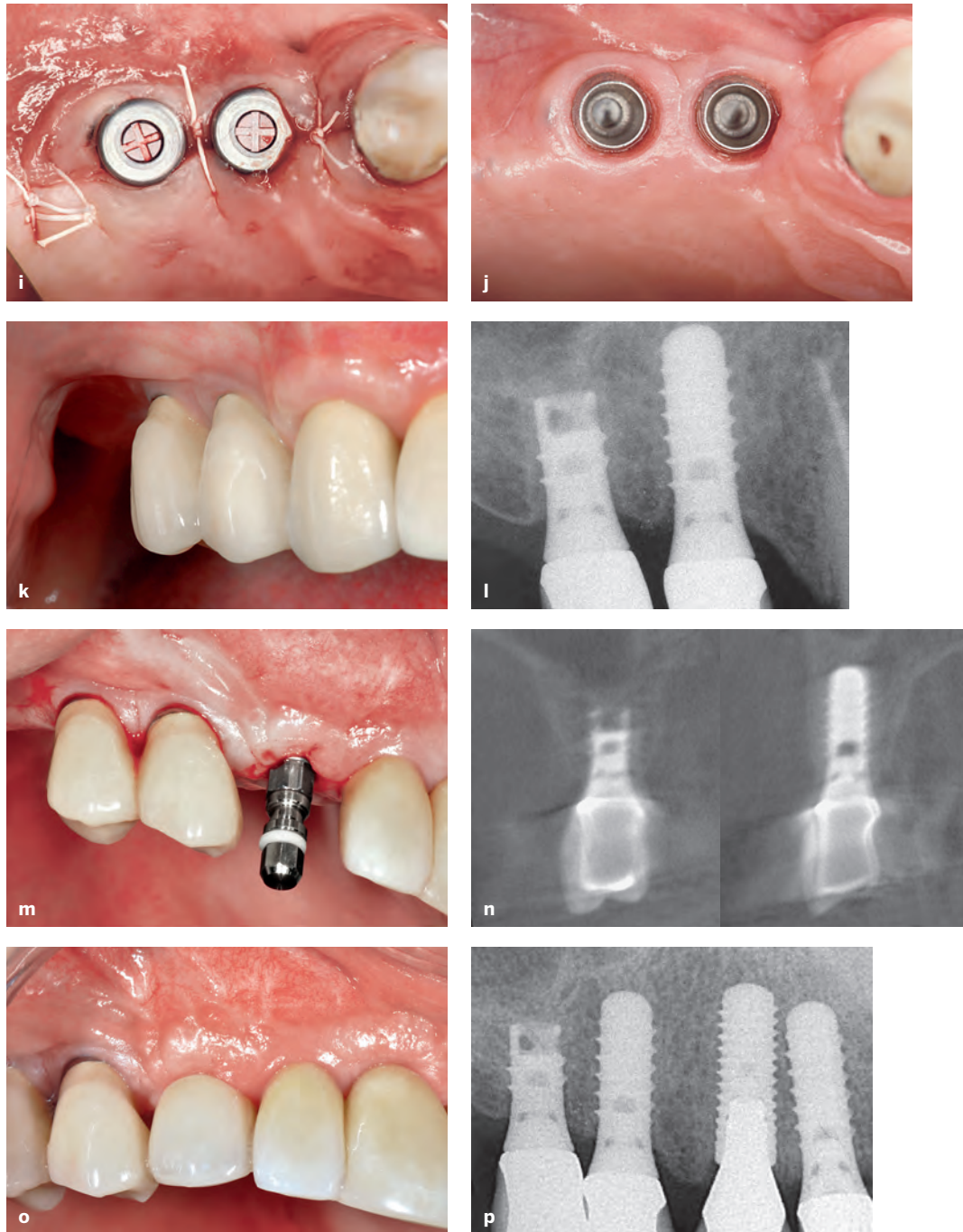
The use of ePTFE membranes for GBR procedures started in the late 1980s. The main objective was to achieve regeneration in peri-implant bone defects in implant sites with local bone deficiencies. The GBR technique has been used with both simultaneous and staged approaches. Implant placement with simultaneous GBR was predominantly used for immediate implant placement in postextraction sites to regenerate peri-implant bone defects<sup>35,36,38</sup> or for implants in sites with crestal dehiscence defects.<sup>40</sup> The staged approach was used in clinical situations with healed ridges but an insufficient crest width. The membrane technique was used to enlarge the crest width with a first surgery, and implant placement took place after 6 to 9 months of healing in a second surgical procedure.<sup>37</sup>

Early on, several complications were observed with both approaches, and modifications of the surgical techniques were proposed to improve the predictability of successful treatment outcomes. One frequent complication was the collapse of the ePTFE membranes, which reduced the volume of the regenerated tissue underneath the membrane. In addition, some of the regenerated sites demonstrated insufficient bone formation and the formation of a periosteum-like tissue underneath the membrane.<sup>37,40</sup> Therefore, bone fillers such as autografts or allografts were recommended by various groups, primarily to support the membrane and reduce the risk of membrane collapse.<sup>54-56</sup> The combination of ePTFE membranes and autogenous bone grafts provided good clinical outcomes for both approaches. Some of these patients are still being followed and documented up to 25 years after surgery (Figs 1-2 to 1-4).

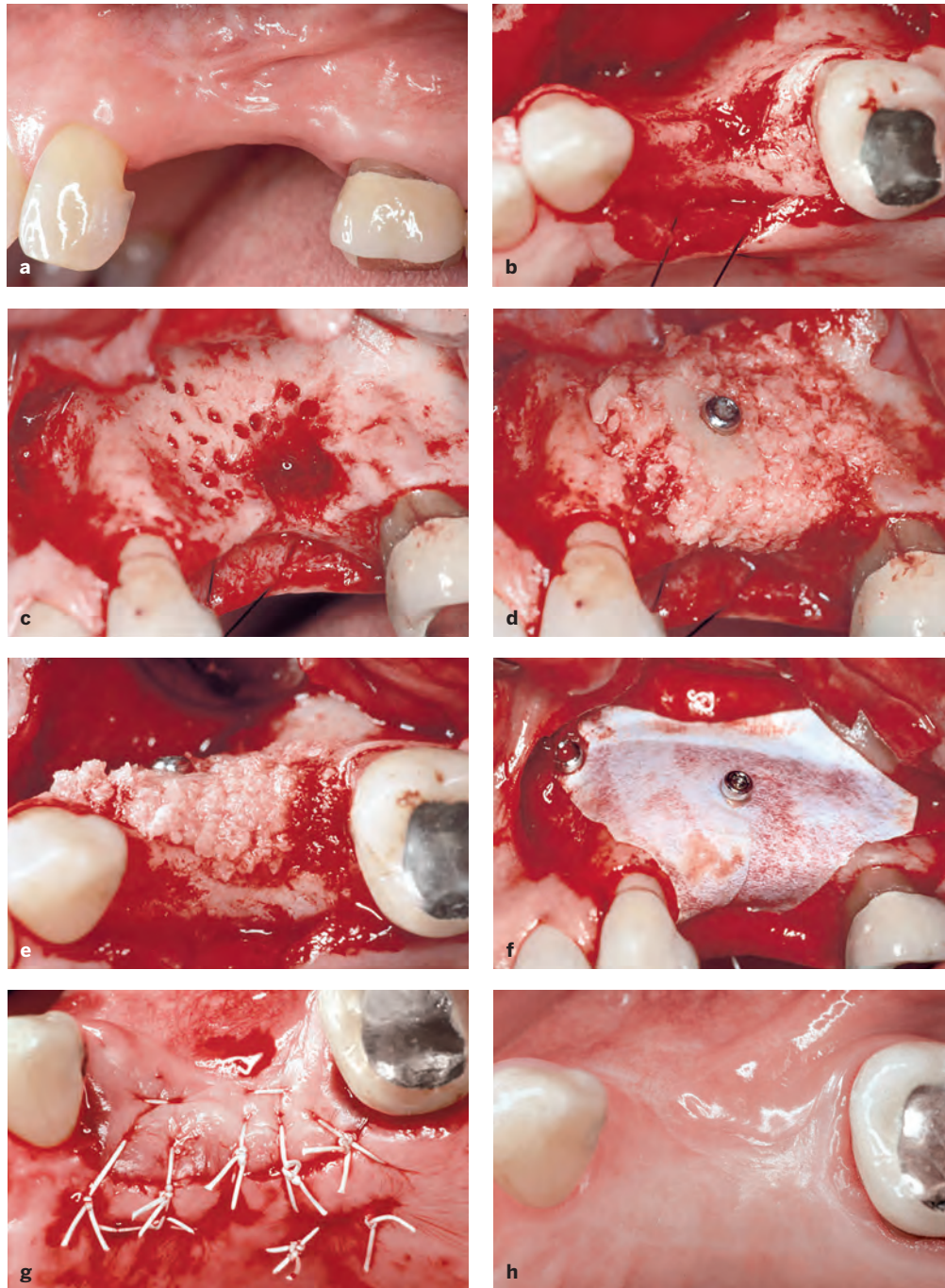




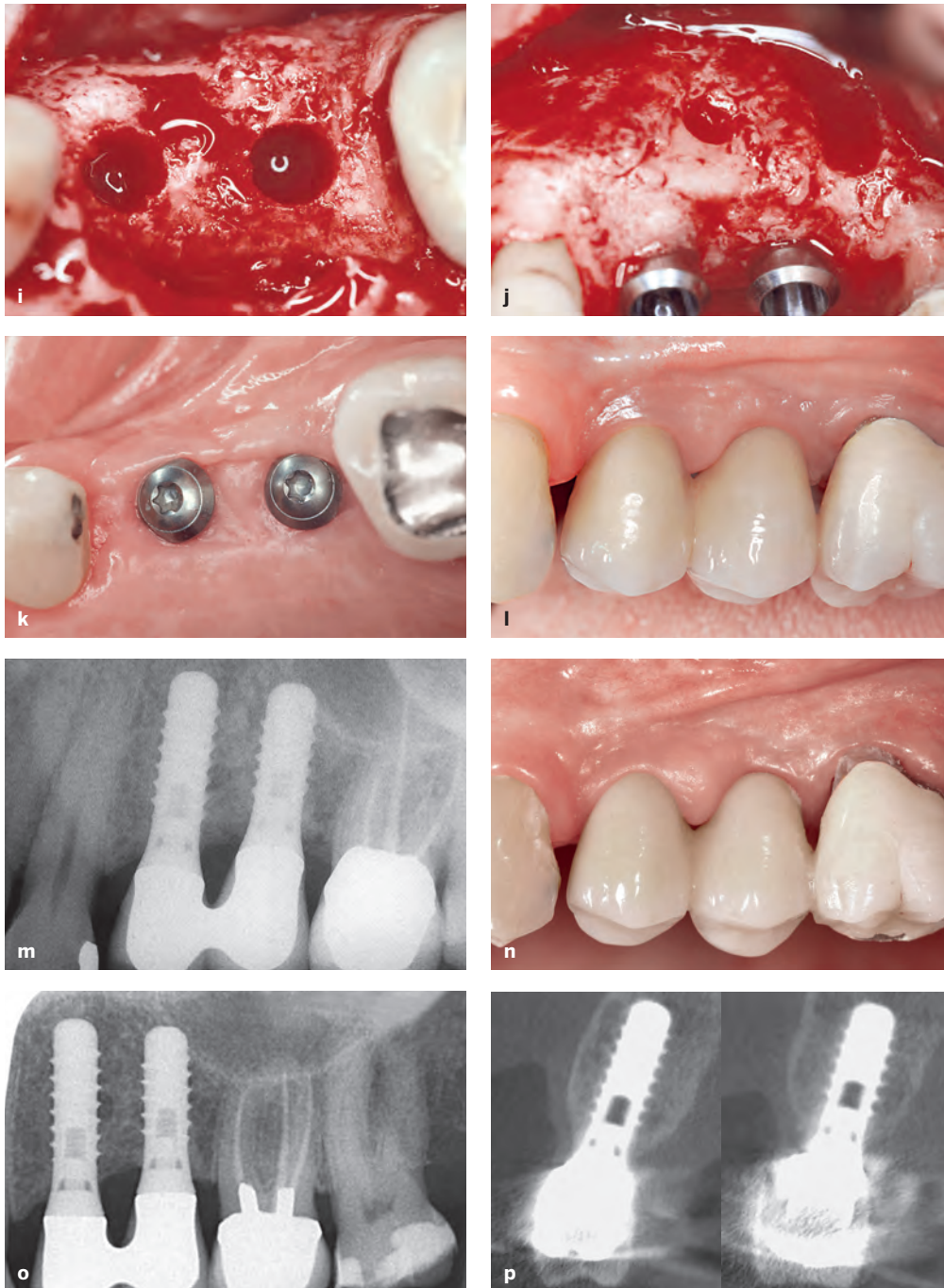
**Fig 1-2 Case 1.** (a) Preoperative status (1991). Distal extension situation in the right maxilla of a man with a healed ridge. Two titanium implants were planned to allow a fixed prosthesis. (b) Both implants were placed, resulting in a crestal dehiscence defect at the mesial implant. The cortical bone surface was perforated with a small round bur to open the marrow cavity and stimulate bleeding in the defect area. (c) Locally harvested bone chips were applied to support the ePTFE membrane and to stimulate new bone formation in the defect area. (d) A bioinert ePTFE membrane was applied to function as a physical barrier. The punched membrane was stabilized around the necks of both implants. (e) Following incision of the periosteum, the surgery was completed with a tension-free primary wound closure. (f) Clinical status 4 months after implant surgery. The wound healing was uneventful. (g) Reopening after 4 months of healing. A second surgery was necessary to remove the nonresorbable membrane. (h) The clinical status following membrane removal showed successful bone regeneration in the defect area at both implants. →



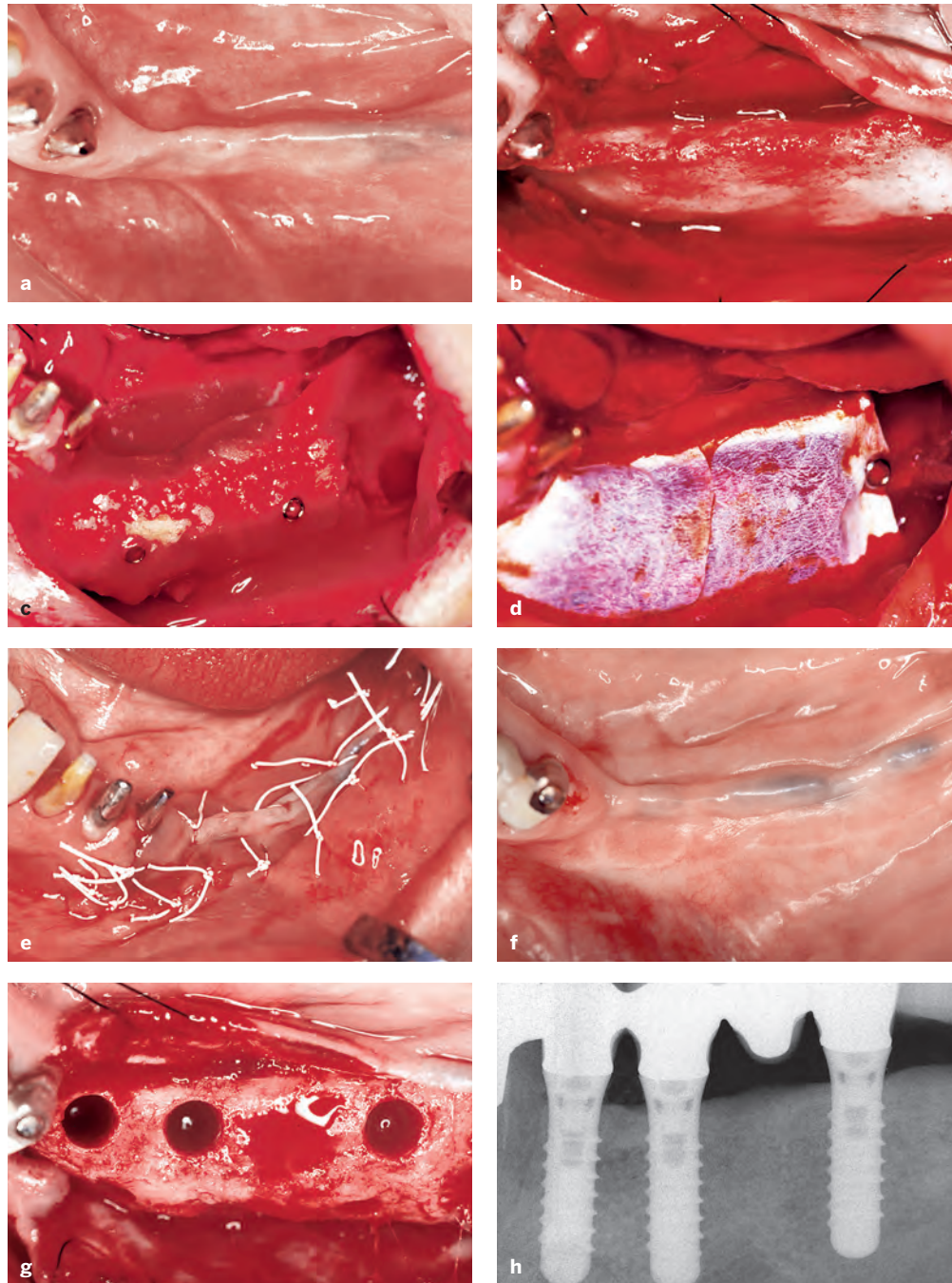
**Fig 1-2 Case 1.** (cont) (i) Longer healing caps were applied, and the soft tissue margins were adapted and secured in place with interrupted sutures. (j) Two weeks later, the soft tissues had healed, and both implants could be restored with a single crown. (k) The clinical status at the 15-year follow-up examination (2006) showed a satisfactory treatment outcome with stable peri-implant soft tissues. (l) Radiographic follow-up at 15 years: The bone crest levels were stable around both implants, which are splinted. (m) In 2010 (19 years after the initial surgery), an additional implant was placed in the canine site as late implant placement with a flapless approach. The clinical view during surgery showed stable peri-implant soft tissue at both implants in the premolar sites. (n) During perioperative examination of the canine implant site, a CBCT scan was taken. The orofacial cuts showed a thick facial bone wall for both premolar implants, which had been in function for 19 years at the time. (o) Clinical status after completion of the new single crown at the canine site. The treatment outcome was very satisfactory considering when the GBR procedure was done (1991). (p) Periapical radiograph after completion of therapy. The two tissue-level implants in the premolar sites had been in function for 19 years, and both showed stable peri-implant bone crest levels. This was the final follow-up examination, as the patient sadly developed dementia and passed away a few years later.



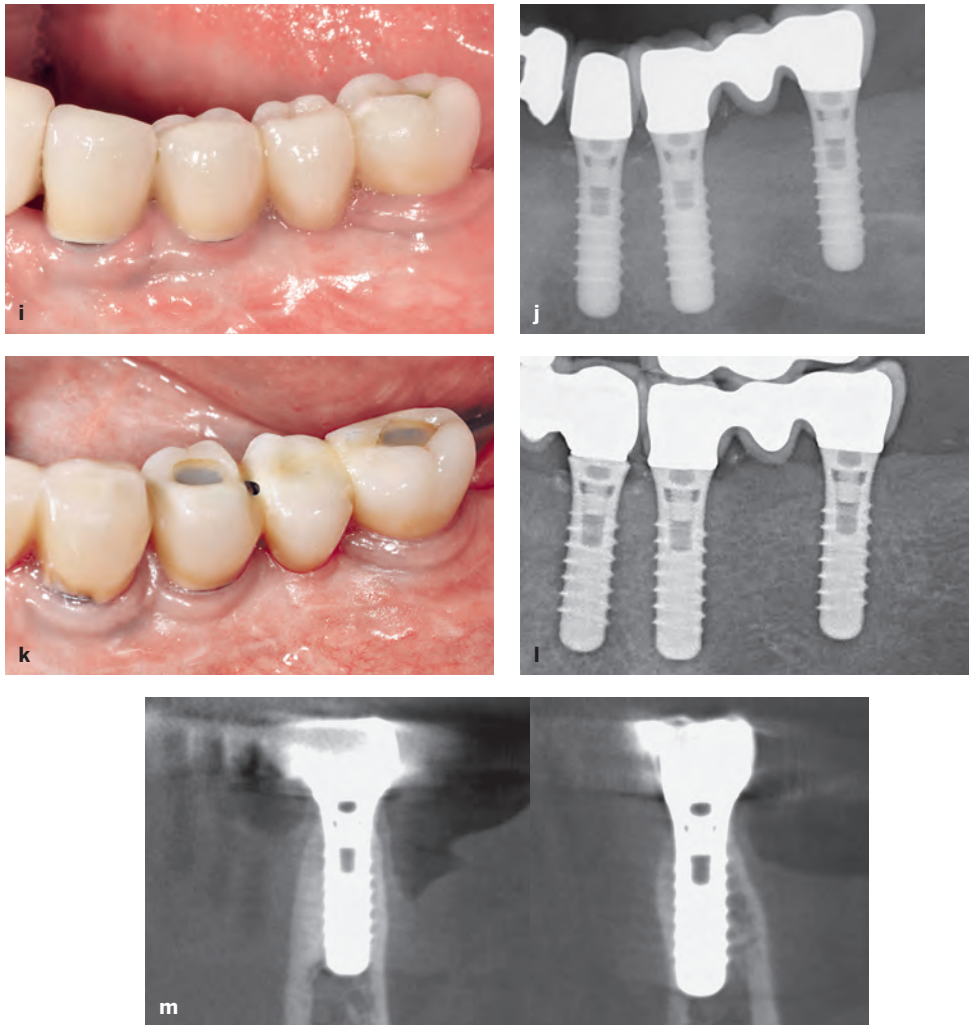
**Fig 1-3 Case 2.** (a) Preoperative view (1994). The buccal view of this woman's left maxilla shows two missing premolars. The buccal aspect is flattened. (b) The occlusal view during surgery shows a significant buccal flattening and a buccal bone defect in the area of the second premolar. (c) Prior to block application, the entire buccal bone surface was perforated to open the marrow cavity. The bone defect was debrided from scar tissues. (d) An autogenous block graft harvested from the chin was applied and fixed with a fixation screw. Bone chips were used to augment the entire surrounding area. (e) The occlusal view shows the volume of the augmented ridge. (f) Buccal view of the applied ePTFE membrane to cover the augmented ridge as a bioinert barrier membrane. (g) Primary wound closure was achieved with several mattress and interrupted single sutures using 4-0 and 5-0 ePTFE sutures. (h) Six months after ridge augmentation, the clinical status shows healthy soft tissues following a healing period free from complications. →



**Fig 1-3 Case 2.** (cont) (i) Following flap elevation and membrane removal, the occlusal view demonstrates an excellent ridge volume and thick buccal bone wall following implant bed preparation. (j) The buccal view confirms successful ridge augmentation. The block graft can still be recognized, and it is covered in some areas with newly formed bone. (k) Clinical status following 3 months of nonsubmerged healing for both implants. The peri-implant mucosa was healthy and included a nice band of keratinized mucosa. (l) Clinical status at the 10-year examination (2005) shows the two splinted implant crowns. The peri-implant mucosa was stable with no signs of a peri-implant pathology. (m) The periapical radiograph at the 10-year examination confirms stable bone crest levels around the two tissue-level implants with a hybrid design. (n) The 25-year follow-up examination (2019) shows the clinical status with quite healthy peri-implant mucosa, although the plaque control is no longer perfect in this elderly patient (age 86). (o) The periapical radiograph confirms stable bone crest levels at both tissue-level implants. (p) The CBCT scan shows fully intact, thick buccal bone walls for the implants in the first premolar (left) and second premolar (right) sites.



**Fig 1-4 Case 3.** (a) Preoperative view (1993). The occlusal view shows a distal extension situation in the left mandible. This woman's healed ridge was atrophic with a severe buccal flattening. (b) The intraoperative view shows a crest width of less than 3 mm. (c) Status following horizontal ridge augmentation with two block grafts harvested in the third molar area within the same flap. (d) The block grafts were covered with an ePTFE membrane. The membrane was stabilized with multiple miniscrews. (e) The surgery was completed with a tension-free wound closure with mattress and single sutures to achieve primary wound healing. (f) Clinical status after 6 months of healing free from complications. (g) Following flap elevation and membrane removal, an excellent augmentation outcome is visible in the areas of the first premolar and first molar, allowing for implants to be placed. (h) Following successful restoration, the periapical radiograph at the 1-year examination (1994) shows stable bone crest levels at all three tissue-level implants. →



**Fig 1-4 Case 3.** (cont) (i) Clinical status at the 15-year examination. The peri-implant mucosa is stable but shows some signs of mucositis. (j) The radiograph confirms stable bone crest levels at all three tissue-level implants. (k) Clinical view at the 25-year follow-up examination (2019). The patient is now 85 years old, and the plaque control is no longer optimal. The mucosa around the tissue-level implants with a machined implant surface in the neck area shows very stable peri-implant tissues. (l) The periapical radiograph confirms stable bone crest levels at all three tissue-level implants after 25 years of function. (m) A CBCT scan is taken to examine the peri-implant bone volume. The orofacial cuts demonstrate fully intact buccal bone walls at the two implants in the first premolar and first molar sites, where a block graft augmentation with GBR was done in 1993.



**Fig 1-5** Photo of the expert meeting in 1994 in Arizona with (from the left) Danny Buser, Bill Becker, Sascha Jovanovic, and Massimo Simion.

### Box 1-1 Objectives for improvements of the GBR technique in the mid 1990s

- Improve the predictability of successful outcomes following GBR
- Reduce the rate of complications due to membrane exposure and membrane infections
- Make the GBR technique more user friendly, with easier application of the membrane during surgery
- Make GBR more patient friendly by eliminating a second surgical procedure for membrane removal whenever possible, and by reducing healing periods as much as possible

In 1994, an expert meeting took place in the United States to discuss the potential and the limitations of the GBR technique used in daily practice after 5 years of clinical experience (Fig 1-5). This meeting clearly showed that improvements of the GBR technique were needed to allow more widespread use in implant patients. The experts agreed that the GBR technique—based on the use of ePTFE membranes in combination with bone grafts or bone substitutes—had the following weaknesses and shortcomings:

- A significant rate of membrane exposures due to soft tissue dehiscences, often leading to local infection beneath the membrane and subsequently to a compromised regenerative outcome of the GBR procedure.<sup>57–60</sup>

- Difficult handling of the membrane during surgery due to its hydrophobic properties, requiring stabilization of the membrane with miniscrews or pins.<sup>55,56,61</sup>
- The need for a second surgical procedure to remove the bioinert, nonresorbable membrane, thereby increasing the morbidity and overall treatment time for the patient.

During this meeting, objectives were defined to improve the predictability and attractiveness of GBR procedures both for implant patients and for clinicians (Box 1-1).

It was clear to the participants at this expert meeting that these objectives could only be achieved with the use of a bioresorbable membrane. This trend was again initiated in the field of GTR, with the

introduction of the first bioresorbable membranes in the early 1990s.<sup>62,63</sup> Subsequently, numerous animal studies were performed to examine different bioresorbable membranes for GBR procedures.<sup>64-74</sup> In general, two different groups of bioresorbable membranes were evaluated<sup>75</sup>:

- Polymeric membranes made of polylactic or polyglycolic acid
- Collagen membranes produced from various animal sources

Paralleling these preclinical studies, clinicians started to use bioresorbable membranes in patients. The first published clinical reports predominantly tested collagen membranes,<sup>76-80</sup> and today, collagen membranes are routinely used in daily practice for GBR procedures.

In addition to selecting an appropriate barrier membrane, the selection of appropriate bone fillers for GBR procedures is just as important for the regenerative outcome of GBR procedures. In the early 1990s, autogenous bone chips were primarily used from a mechanical point of view. The role of these filler particles was to support the membrane to avoid a membrane collapse during healing. In the mid 1990s, a first preclinical study in minipigs by Buser et al<sup>81</sup> helped us to understand that bone fillers have different biologic characteristics in terms of their osteogenic potential and rate of filler substitution during bone remodeling.

The various biomaterials used for GBR procedures, such as bone grafts, bone substitutes, and barrier membranes, are also discussed in chapter 2.

## Routine Application and Fine-Tuning Phase of GBR

Around the year 2000, GBR entered a phase of routine application in daily practice. Since then, the GBR technique has been the standard of care for the regeneration of localized bony defects in implant patients. This was confirmed in 2007 in a systematic review by Aghaloo and Moy,<sup>82</sup> who demonstrated that implants

placed with the GBR procedure have favorable survival and success rates, and the GBR procedure was the only well-documented surgical technique among various surgical techniques used for localized ridge augmentation. The only other scientifically well-documented surgical technique for bone augmentation at that time was sinus grafting and sinus floor elevation in the posterior maxilla.

Over the past 20 years, however, significant progress has been made with GBR procedures, thanks to new developments in technology and a much better understanding of the tissue and graft biology involved.

The most important improvements are as follows:

- The development of a much better 3D radiographic technique based on CBCT
- Much greater knowledge of tissue biology in postextraction sites
- A much better understanding of the biologic characteristics of bone grafts and bone substitutes
- The development of new narrow-diameter implants

### *CBCT as the new 3D radiographic methodology*

The development of the CBCT technique started in the late 1990s with a first publication by Mozzo et al,<sup>83</sup> and it represents probably one of the most important improvements in implant dentistry in the past 20 years. This new 3D radiographic technique allowed cross-sectional imaging with much better image quality and a clear reduction in radiation exposure when compared with the computed tomography (CT) technology used for dentistry in the 1990s. The CBCT technique allows cross-sectional imaging not only for the preoperative examination of patients, but also for the follow-up documentation of bone augmentation procedures.<sup>84,85</sup> During preoperative examination, CBCT helps to assess the extent of bone deficiencies in potential implant sites, and hence to categorize defect morphologies. These aspects are discussed in detail in chapter 5. In addition, CBCT is also one of the basic techniques necessary for the use of digital technology, including computer-assisted implant surgery (CAIS) in patients.



### *Improved knowledge of tissue biology in postextraction sites*

The progress in this field was initiated around 2004 to 2005 by fundamental studies on bone alterations in postextraction sites performed by the group of Lindhe et al. In the beginning, a series of experimental studies in beagle dogs helped to explain the concept of bundle bone resorption postextraction.<sup>86,87</sup> These studies were followed by a number of clinical studies using the CBCT technique (for review, see Chappuis et al<sup>88</sup>). This new knowledge was fundamental for the definition of selection criteria used in postextraction implant placement. The current knowledge of hard and soft tissue alterations is discussed in detail in chapter 4, and the selection criteria for the different treatment options are presented in chapter 6.

### *Better understanding of the biologic characteristics of bone grafts and bone substitutes*

As mentioned in a previous paragraph, autogenous bone chips had already been utilized with GBR procedures in the late 1980s, but they were used primarily as membrane support to avoid membrane collapse during healing. In the late 1990s, a first preclinical study by Buser et al<sup>81</sup> in minipigs showed that bone fillers have different biologic characteristics. Autogenous bone chips have excellent osteogenic potential, fostering new bone formation during early healing, and have a high substitution rate during bone remodeling. The alternative bone fillers tested were all associated with much slower bone formation during early healing, but one of them showed an interesting low substitution rate. Subsequently, a series of experimental studies with various bone fillers were conducted by Jensen et al,<sup>89-91</sup> confirming the superiority of autogenous bone chips with regard to osteogenic potential in comparison with all other bone fillers tested. In contrast, these studies showed that some bone fillers had very good volume stability with a low substitution rate, such as deproteinized bovine bone mineral (DBBM), a bovine bone filler. This new insight into the biologic properties of bone grafts and bone substitutes increasingly favored the use of two bone fillers as a so-called

*composite graft*, which can be used either as a two-layer or a mixed composite graft (see chapter 2).

In the 2010s, the characteristics of autogenous bone chips were further examined in a series of in vitro studies using cell cultures. The studies showed that these bone chips instantly release growth factors (GFs) such as transforming growth factor  $\beta$ 1 (TGF- $\beta$ 1) and bone morphogenetic protein 2 (BMP-2) into the surrounding blood, both potent GFs for osteogenesis.<sup>92-95</sup> With this release of GFs, the blood containing them is called *bone-conditioned medium* (BCM). BCM is then able to biologically activate bone fillers and barrier membranes for GBR procedures.<sup>96,97</sup> All these details are presented in this textbook in a completely new chapter 3.

### *Development of new narrow-diameter implants made of a Ti-Zr alloy*

Narrow-diameter implants (NDIs) made of commercially pure titanium (CPTi) were already available in the mid 1990s, but they had limited clinical applications because NDIs showed an increased fracture rate in daily practice due to fatigue fractures.<sup>98</sup> To reduce the risk of fracture, splinting NDIs to other implants was recommended at that time.<sup>8</sup> Around 2010, a new titanium-zirconium (Ti-Zr) alloy called Roxolid (Straumann) was introduced to the market. This new implant material offered much greater strength when compared with CPTi.<sup>99</sup> The stronger implant material was able to reduce the risk of fracture, and hence widened the range of applications in daily practice. In the meantime, NDIs became well documented by clinical studies and systematic reviews.<sup>100-103</sup> In the most recent patient pool analysis, covering 3 years (2014 to 2016) at the University of Bern, the frequency of NDIs clearly increased, to roughly 25%.<sup>21</sup> This means their use has remarkably more than doubled in a 6-year period.<sup>20</sup>

The utilization of NDIs has two advantages in daily practice. First, it allows the clinician to use a standard implant placement protocol without a simultaneous GBR procedure in borderline situations with a crest width of around 6 mm. Second, in case of a local bone defect, it optimizes the defect morphology following implant placement and hence reduces the frequency

of staged approach augmentation procedures. The benefit for patients is obvious, because it reduces not only morbidity, but also costs. These details are discussed in chapter 5 of this textbook.

All these developments have enabled us to fine-tune the GBR technique in the past 20 years, and the details of these aspects are discussed in the clinical chapters of this book.

## Summary

Over the years, significant progress has been made with GBR procedures in implant patients. GBR has not only become the standard of care for the regeneration of localized bone defects in the alveolar ridge of potential implant patients, but it has been an important contributing factor for the rapid expansion of implant therapy in the past 20 years, as well as contributing to significant progress in the field of esthetic implant dentistry.

The procedures recommended in various clinical situations are presented step-by-step in chapters 6 to 13. The reader of this textbook will quickly realize that the recommended surgical techniques are rather conservative, following basic rules of bone augmentation procedures. This offers the clinician the most predictable approach to achieving a successful treatment outcome with a low risk of complications, and thus the ability to become a successful implant surgeon who is able to satisfy the high expectations of today's patients.

## References

1. Buser D, Sennerby L, De Bruyn H. Modern implant dentistry based on osseointegration: 50 years of progress, current trends and open questions. *Periodontol 2000* 2017;73:7–21.
2. Brånemark P-I, Adell R, Breine U, Hansson BO, Lindström J, Ohlsson A. Intra-osseous anchorage of dental prostheses. I. Experimental studies. *Scand J Plast Reconstr Surg* 1969;3:81–100.
3. Schroeder A, Pohler O, Sutter F. Tissue reaction to an implant of a titanium hollow cylinder with a titanium surface spray layer [in German]. *SSO Schweiz Monatsschr Zahnmed* 1976;86:713–727.
4. Schroeder A, van der Zypen E, Stich H, Sutter F. The reactions of bone, connective tissue, and epithelium to endosteal implants with titanium-sprayed surfaces. *J Maxillofac Surg* 1981;9:15–25.
5. Albrektsson T, Brånemark P-I, Hansson H-A, Lindström J. Osseointegrated titanium implants. Requirements for ensuring a long-lasting direct bone-to-implant anchorage in man. *Acta Orthop Scand* 1981;52:155–170.
6. Schenk RK, Buser D. Osseointegration: A reality. *Periodontol 2000* 1998;17:22–35.
7. Bosshardt DD, Chappuis V, Buser D. Osseointegration of titanium, titanium alloy and zirconia dental implants: Current knowledge and open questions. *Periodontol 2000* 2017;73:22–40.
8. Buser D, von Arx T, ten Bruggenkate C, Weingart D. Basic surgical principles with ITI implants. *Clin Oral Implants Res* 2000;11(suppl 1):59–68.
9. Gotfredsen K, Rostrup E, Hjørting-Hansen E, Stoltze K, Budtz-Jørgensen E. Histological and histomorphometrical evaluation of tissue reactions adjacent to endosteal implants in monkeys. *Clin Oral Implants Res* 1991;2:30–37.
10. Weber HP, Buser D, Donath K, et al. Comparison of healed tissues adjacent to submerged and non-submerged unloaded titanium dental implants. A histometric study in beagle dogs. *Clin Oral Implants Res* 1996;7:11–19.
11. Brånemark P-I, Hansson BO, Adell R, et al. Osseointegrated implants in the treatment of the edentulous jaw. Experience from a 10-year period. *Scand J Plast Reconstr Surg* 1977;16(suppl):1–132.
12. Adell R, Lekholm U, Rockler B, Brånemark P-I. A 15-year study of osseointegrated implants in the treatment of the edentulous jaw. *Int J Oral Surg* 1981;10:387–416.
13. Albrektsson T, Dahl E, Enbom L, et al. Osseointegrated oral implants. A Swedish multicenter study of 8139 consecutively inserted Nobelpharma implants. *J Periodontol* 1988;59:287–296.
14. Jemt T, Lekholm U, Adell R. Osseointegrated implants in the treatment of partially edentulous patients: A preliminary study on 876 consecutively placed fixtures. *Int J Oral Maxillofac Implants* 1989;4:211–217.
15. Buser D, Weber HP, Lang NP. Tissue integration of non-submerged implants. 1-year results of a prospective study with 100 ITI hollow-cylinder and hollow-screw implants. *Clin Oral Implants Res* 1990;1:33–40.
16. Buser D, Weber HP, Bragger U, Balsiger C. Tissue integration of one-stage ITI implants: 3-year results of a longitudinal study with hollow-cylinder and hollow-screw implants. *Int J Oral Maxillofac Implants* 1991;6:405–412.
17. Zarb GA, Schmitt A. The longitudinal clinical effectiveness of osseointegrated dental implants in anterior partially edentulous patients. *Int J Prosthodont* 1993;6:180–188.
18. Zarb GA, Schmitt A. The longitudinal clinical effectiveness of osseointegrated dental implants in posterior partially edentulous patients. *Int J Prosthodont* 1993;6:189–196.
19. Bornstein MM, Halbritter S, Harnisch H, Weber HP, Buser D. A retrospective analysis of patients referred for implant placement to a specialty clinic: Indications, surgical procedures, and early failures. *Int J Oral Maxillofac Implants* 2008;23:1109–1116.
20. Brügger OE, Bornstein MM, Kuchler U, Janner SFM, Chappuis V, Buser D. Implant therapy in a surgical specialty clinic: An analysis of patients, indications, surgical procedures, risk factors, and early failures. *Int J Oral Maxillofac Implants* 2015;30:151–160.
21. Ducommun J, El Kholy K, Rahman L, Schimmel M, Chappuis V, Buser D. Analysis of trends in implant therapy at a surgical specialty clinic: Patient pool, indications, surgical procedures, and rate of early failures—A 15-year retrospective analysis. *Clin Oral Implants Res* 2019;30:1097–1106.

22. Lekholm U, Adell R, Lindhe J, et al. Marginal tissue reactions at osseointegrated titanium fixtures. (II) A cross-sectional retrospective study. *Int J Oral Maxillofac Surg* 1986;15:53–61.
23. Dietrich U, Lippold R, Dirmeier T, Behneke W, Wagner W. Statistische Ergebnisse zur Implantatprognose am Beispiel von 2017 IMZ-Implantaten unterschiedlicher Indikationen der letzten 13 Jahre. *Z Zahnärztl Implantol* 1993;9:9–18.
24. Lindstrom J, Brånemark P-I, Albrektsson T. Mandibular reconstruction using the preformed autologous bone graft. *Scand J Plastic Reconstr Surg* 1981;15:29–38.
25. Jensen J, Sindet-Pedersen S. Autogenous mandibular bone grafts and osseointegrated implants for reconstruction of the severely atrophied maxilla: A preliminary report. *J Oral Maxillofac Surg* 1991;49:1277–1287.
26. Boyne PJ, James RA. Grafting of the maxillary sinus floor with autogenous marrow and bone. *J Oral Surg* 1980;38:613–616.
27. Wood RM, Moore DL. Grafting of the maxillary sinus with intraorally harvested autogenous bone prior to implant placement. *Int J Oral Maxillofac Implants* 1988;3:209–214.
28. Kent JN, Block MS. Simultaneous maxillary sinus floor bone grafting and placement of hydroxylapatite-coated implants. *J Oral Maxillofac Surg* 1989;47:238–242.
29. Ten Bruggenkate CM, Kraaijenhagen HA, van der Kwast WA, Krekeler G, Oosterbeek HS. Autogenous maxillary bone grafts in conjunction with placement of I.T.I. endosseous implants. A preliminary report. *Int J Oral Maxillofac Surg* 1992;21:81–84.
30. Triplett RG, Schow SR. Autologous bone grafts and endosseous implants: Complementary techniques. *J Oral Maxillofac Surg* 1996;54:486–494.
31. Widmark G, Andersson B, Ivanoff CJ. Mandibular bone graft in the anterior maxilla for single-tooth implants. Presentation of surgical method. *Int J Oral Maxillofac Surg* 1997;26:106–109.
32. Osborn JF. Die Alveolar-Extensions Plastik. *Quintessenz* 1985;36:9–16.
33. Khoury F. Die modifizierte Alveolar-Extensions Plastik. *Z Zahnärztl Implantol* 1987;3:174.
34. Simion M, Baldoni M, Zaffe D. Jawbone enlargement using immediate implant placement associated with a split-crest technique and guided tissue regeneration. *Int J Periodontics Restorative Dent* 1992;12:462–473.
35. Lazzara RJ. Immediate implant placement into extraction sites: Surgical and restorative advantages. *Int J Periodontics Restorative Dent* 1989;9:332–343.
36. Nyman S, Lang NP, Buser D, Brägger U. Bone regeneration adjacent to titanium dental implants using guided tissue regeneration: A report of two cases. *Int J Oral Maxillofac Implants* 1990;5:9–14.
37. Buser D, Brägger U, Lang NP, Nyman S. Regeneration and enlargement of jaw bone using guided tissue regeneration. *Clin Oral Implants Res* 1990;1:22–32.
38. Becker W, Becker BE. Guided tissue regeneration for implants placed into extraction sockets and for implant dehiscences: Surgical techniques and case reports. *Int J Periodontics Restorative Dent* 1990;10:376–391.
39. Dahlin C, Andersson L, Linde A. Bone augmentation at fenestrated implants by an osteopromotive membrane technique. A controlled clinical study. *Clin Oral Implants Res* 1991;2:159–165.
40. Jovanovic SA, Spiekermann H, Richter EJ. Bone regeneration around titanium dental implants in dehiscence defect sites: A clinical study. *Int J Oral Maxillofac Implants* 1992;7:233–245.
41. Nyman S, Lindhe J, Karring T, Rylander H. New attachment following surgical treatment of human periodontal disease. *J Clin Periodontol* 1982;9:290–296.
42. Nyman S, Gottlow J, Karring T, Lindhe J. The regenerative potential of the periodontal ligament. An experimental study in the monkey. *J Clin Periodontol* 1982;9:257–265.
43. Hurley LA, Stinchfield FE, Bassett AL, Lyon WH. The role of soft tissues in osteogenesis. An experimental study of canine spine fusions. *J Bone Joint Surg Am* 1959;41a:1243–1254.
44. Bassett CAL, Creighton DK, Stinchfield FE. Contributions of endosteum, cortex, and soft tissues to osteogenesis. *Surg Gynecol Obstet* 1961;112:145.
45. Boyne PJ. Regeneration of alveolar bone beneath cellulose acetate filter implants. *J Dent Res* 1964;43:827.
46. Gottlow J, Nyman S, Karring T, Lindhe J. New attachment formation as the result of controlled tissue regeneration. *J Clin Periodontol* 1984;11:494–503.
47. Gottlow J, Nyman S, Lindhe J, Karring T, Wennström J. New attachment formation in the human periodontium by guided tissue regeneration. Case reports. *J Clin Periodontol* 1986;13:604–616.
48. Pontoriero R, Nyman S, Lindhe J, Rosenberg E, Sanavi F. Guided tissue regeneration in the treatment of furcation defects in man. *J Clin Periodontol* 1987;14:618–620.
49. Pontoriero R, Lindhe J, Nyman S, Karring T, Rosenberg E, Sanavi F. Guided tissue regeneration in the treatment of furcation defects in mandibular molars. A clinical study of degree III involvements. *J Clin Periodontol* 1989;16:170–174.
50. Dahlin C, Linde A, Gottlow J, Nyman S. Healing of bone defects by guided tissue regeneration. *Plast Reconstr Surg* 1988;81:672–676.
51. Dahlin C, Sennerby L, Lekholm U, Linde A, Nyman S. Generation of new bone around titanium implants using a membrane technique: An experimental study in rabbits. *Int J Oral Maxillofac Implants* 1989;4:19–25.
52. Dahlin C, Gottlow J, Linde A, Nyman S. Healing of maxillary and mandibular bone defects using a membrane technique. An experimental study in monkeys. *Scand J Plast Reconstr Surg Hand Surg* 1990;24:13–19.
53. Schenk RK, Buser D, Hardwick WR, Dahlin C. Healing pattern of bone regeneration in membrane-protected defects: A histologic study in the canine mandible. *Int J Oral Maxillofac Implants* 1994;9:13–29.
54. Nevins M, Mellonig JT. Enhancement of the damaged edentulous ridge to receive dental implants: A combination of allograft and the GORE-TEX membrane. *Int J Periodontics Restorative Dent* 1992;12:96–111.
55. Buser D, Dula K, Belser U, Hirt HP, Berthold H. Localized ridge augmentation using guided bone regeneration. I. Surgical procedure in the maxilla. *Int J Periodontics Restorative Dent* 1993;13:29–45.
56. Buser D, Dula K, Belser UC, Hirt HP, Berthold H. Localized ridge augmentation using guided bone regeneration. II. Surgical procedure in the mandible. *Int J Periodontics Restorative Dent* 1995;15:10–29.
57. Becker W, Dahlin C, Becker BE, et al. The use of e-PTFE barrier membranes for bone promotion around titanium implants placed into extraction sockets: A prospective multicenter study. *Int J Oral Maxillofac Implants* 1994;9:31–40.
58. Gotfredsen K, Nimb L, Buser D, Hjørting-Hansen E. Evaluation of guided bone generation around implants placed into fresh extraction sockets: An experimental study in dogs. *J Oral Maxillofac Surg* 1993;51:879–884.
59. Augthun M, Yildirim M, Spiekermann H, Biesterfeld S. Healing of bone defects in combination with immediate implants using the membrane technique. *Int J Oral Maxillofac Implants* 1995;10:421–428.
60. Rosenquist B, Grenthe B. Immediate placement of implants into extraction sockets: Implant survival. *Int J Oral Maxillofac Implants* 1996;11:205–209.

61. Becker W, Becker BE, McGuire MK. Localized ridge augmentation using absorbable pins and e-PTFE barrier membranes: A new surgical approach. Case reports. *Int J Periodontics Restorative Dent* 1994;14:48–61.
62. Gottlow J. Guided tissue regeneration using bioresorbable and non-resorbable devices: Initial healing and long-term results. *J Periodontol* 1993;64(11 suppl):1157–1165.
63. Gottlow J, Laurell L, Lundgren D, et al. Periodontal tissue response to a new bioresorbable guided tissue regeneration device: A longitudinal study in monkeys. *Int J Periodontics Restorative Dent* 1994;14:436–449.
64. Aaboe M, Pinholt EM, Hjørting-Hansen E, Solheim E, Praetorius F. Guided tissue regeneration using degradable and nondegradable membranes in rabbit tibia. *Clin Oral Implants Res* 1993;4:172–176.
65. Gotfredsen K, Nimb L, Hjørting-Hansen E. Immediate implant placement using a biodegradable barrier, polyhydroxybutyrate-hydroxyvalerate reinforced with polyglactin 910. An experimental study in dogs. *Clin Oral Implants Res* 1994;5:83–91.
66. Schliephake H, Neukam FW, Hutmacher D, Becker J. Enhancement of bone ingrowth into a porous hydroxylapatite-matrix using a resorbable polylactic membrane: An experimental pilot study. *J Oral Maxillofac Surg* 1994;52:57–63.
67. Hürzeler MB, Quiñones CR, Schüpbach P. Guided bone regeneration around dental implants in the atrophic alveolar ridge using a bioresorbable barrier. An experimental study in the monkey. *Clin Oral Implants Res* 1997;8:323–331.
68. Schliephake H, Kracht D. Vertical ridge augmentation using polylactic membranes in conjunction with immediate implants in periodontally compromised extraction sites: An experimental study in dogs. *Int J Oral Maxillofac Implants* 1997;12:325–334.
69. Hürzeler MB, Kohal RJ, Naghshbandi J, et al. Evaluation of a new bioresorbable barrier to facilitate guided bone regeneration around exposed implant threads. An experimental study in the monkey. *Int J Oral Maxillofac Surg* 1998;27:315–320.
70. Hockers T, Abensur D, Valentini P, Legrand R, Hammerle CH. The combined use of bioresorbable membranes and xenografts or autografts in the treatment of bone defects around implants. A study in beagle dogs. *Clin Oral Implants Res* 1999;10:487–498.
71. Alliot B, Piotrowski B, Marin P, Zahedi S, Brunel G. Regeneration procedures in immediate transmucosal implants: An animal study. *Int J Oral Maxillofac Implants* 1999;14:841–848.
72. von Arx T, Cochran DL, Schenk RK, Buser D. Evaluation of a prototype trilayer membrane (PTLM) for lateral ridge augmentation: An experimental study in the canine mandible. *Int J Oral Maxillofac Surg* 2002;31:190–199.
73. Donos N, Kostopoulos L, Karring T. Alveolar ridge augmentation using a resorbable copolymer membrane and autogenous bone grafts. An experimental study in the rat. *Clin Oral Implants Res* 2002;13:203–213.
74. Oh TJ, Meraw SJ, Lee EJ, Giannobile WV, Wang H-L. Comparative analysis of collagen membranes for the treatment of implant dehiscence defects. *Clin Oral Implants Res* 2003;14:80–90.
75. Hutmacher D, Hürzeler MB, Schliephake H. A review of material properties of biodegradable and bioresorbable polymers and devices for GTR and GBR applications. *Int J Oral Maxillofac Implants* 1996;11:667–678.
76. Hürzeler MB, Strub JR. Guided bone regeneration around exposed implants: A new bioresorbable device and bioresorbable membrane pins. *Pract Periodontics Aesthet Dent* 1995;7:37–47.
77. Zitzmann NU, Naef R, Schärer P. Resorbable versus nonresorbable membranes in combination with Bio-Oss for guided bone regeneration. *Int J Oral Maxillofac Implants* 1997;12:844–852.
78. Zitzmann NU, Scharer P, Marinello CP. Factors influencing the success of GBR. Smoking, timing of implant placement, implant location, bone quality and provisional restoration. *J Clin Periodontol* 1999;26:673–682.
79. Nemcovsky CE, Artzi Z, Moses O, Gelernter I. Healing of dehiscence defects at delayed-immediate implant sites primarily closed by a rotated palatal flap following extraction. *Int J Oral Maxillofac Implants* 2000;15:550–558.
80. Hammerle CH, Lang NP. Single stage surgery combining transmucosal implant placement with guided bone regeneration and bioresorbable materials. *Clin Oral Implants Res* 2001;12:9–18.
81. Buser D, Hoffmann B, Bernard JP, Lussi A, Mettler D, Schenk RK. Evaluation of filling materials in membrane-protected bone defects. A comparative histomorphometric study in the mandible of miniature pigs. *Clin Oral Implants Res* 1998;9:137–150.
82. Aghaloo TL, Moy PK. Which hard tissue augmentation techniques are the most successful in furnishing bony support for implant placement? *Int J Oral Maxillofac Implants* 2007;(22 suppl):49–70.
83. Mozzo P, Procacci C, Tacconi A, Tinazzi Martini P, Bergamo Andreis IA. A new volumetric CT machine for dental imaging based on the cone-beam technique: Preliminary results. *Eur Radiol* 1998;8:1558–1564.
84. Harris D, Horner K, Gröndahl K, et al. E.A.O. guidelines for the use of diagnostic imaging in implant dentistry 2011: A consensus workshop organized by the European Association for Osseointegration at the Medical University of Warsaw. *Clin Oral Implants Res* 2012;23:1243–1253.
85. Bornstein MM, Scarfe WC, Vaughn VM, Jacobs R. Cone beam computed tomography in implant dentistry: A systematic review focusing on guidelines, indications, and radiation dose risks. *Int J Oral Maxillofac Implants* 2014;29(suppl):55–77.
86. Cardaropoli G, Araújo M, Lindhe J. Dynamics of bone tissue formation in tooth extraction sites: An experimental study in dogs. *J Clin Periodontol* 2003;30:809–818.
87. Araújo MG, Lindhe J. Dimensional ridge alterations following tooth extraction. An experimental study in the dog. *J Clin Periodontol* 2005;32:212–218.
88. Chappuis V, Araújo MG, Buser D. Clinical relevance of dimensional bone and soft tissue alterations post-extraction in esthetic sites. *Periodontology* 2000 2017;73:73–83.
89. Jensen SS, Brogini N, Hjørting-Hansen E, Schenk R, Buser D. Bone healing and graft resorption of autograft, anorganic bovine bone and beta-tricalcium phosphate. A histologic and histomorphometric study in the mandibles of minipigs. *Clin Oral Implants Res* 2006;17:237–243.
90. Jensen SS, Yeo A, Dard M, Hunziker E, Schenk R, Buser D. Evaluation of a novel biphasic calcium phosphate in standardized bone defects: A histologic and histomorphometric study in the mandibles of minipigs. *Clin Oral Implants Res* 2007;18:752–760.
91. Jensen SS, Bornstein MM, Dard M, Bosshardt DD, Buser D. Comparative study of biphasic calcium phosphates with different HA/TCP ratios in mandibular bone defects. A long-term histomorphometric study in minipigs. *J Biomed Mater Res B Appl Biomater* 2009;90:171–181.
92. Miron RJ, Hedborn E, Saulacic N, et al. Osteogenic potential of autogenous bone grafts harvested with four different surgical techniques. *J Dent Res* 2011;90:1428–1433.

93. Miron RJ, Gruber R, Hedbom E, et al. Impact of bone harvesting techniques on cell viability and the release of growth factors of autografts. *Clin Implant Dent Relat Res* 2013;15:481–489.
94. Caballé-Serrano J, Bosshardt DD, Buser D, Gruber R. Proteomic analysis of porcine bone-conditioned medium. *Int J Oral Maxillofac Implants* 2014;29:1208–1215.
95. Asparuhova M, Caballé-Serrano J, Buser D, Chappuis V. Bone-conditioned medium contributes to initiation and progression of osteogenesis by exhibiting synergistic TGF- $\beta$ 1/BMP-2 activity. *Int J Oral Sci* 2018;10:20.
96. Caballé-Serrano J, Fujioka-Kobayashi M, Bosshardt DD, Gruber R, Buser D, Miron RJ. Pre-coating deproteinized bovine bone mineral (DBBM) with bone-conditioned medium (BCM) improves osteoblast migration, adhesion, and differentiation in vitro. *Clin Oral Investig* 2016;20:2507–2513.
97. Caballé-Serrano J, Sawada K, Miron RJ, Bosshardt DD, Buser D, Gruber R. Collagen barrier membranes adsorb growth factors liberated from autogenous bone chips. *Clin Oral Implants Res* 2017;28:236–241.
98. Allum SR, Tomlinson RA, Joshi R. The impact of loads on standard diameter, small diameter and mini implants: A comparative laboratory study. *Clin Oral Implants Res* 2008;19:553–559.
99. Kobayashi E, Matsumoto S, Doi H, Yoneyama T, Hamanaka H. Mechanical properties of the binary titanium-zirconium alloys and their potential for biomedical materials. *J Biomed Mater Res* 1995;29:943–950.
100. Al-Nawas B, Domagala P, Fragola G, et al. A prospective noninterventional study to evaluate survival and success of reduced diameter implants made from titanium-zirconium alloy. *J Oral Implantol* 2015;41:e118–e125.
101. Quirynen M, Al-Nawas B, Meijer HJA, et al; Roxolid Study Group. Small-diameter titanium grade IV and titanium-zirconium implants in edentulous mandibles: Three-year results from a double-blind, randomized controlled trial. *Clin Oral Implants Res* 2015;26:831–840.
102. Müller F, Al-Nawas B, Storelli S, et al; Roxolid Study Group. Small-diameter titanium grade IV and titanium-zirconium implants in edentulous mandibles: Five-year results from a double-blind, randomized controlled trial. *BMC Oral Health* 2015;15:123.
103. Schiegnitz E, Al-Nawas B. Narrow-diameter implants: A systematic review and meta-analysis. *Clin Oral Implants Res* 2018;29(suppl 16):21–40.