Mario Goisis
Editor

Outpatient Regenerative Medicine

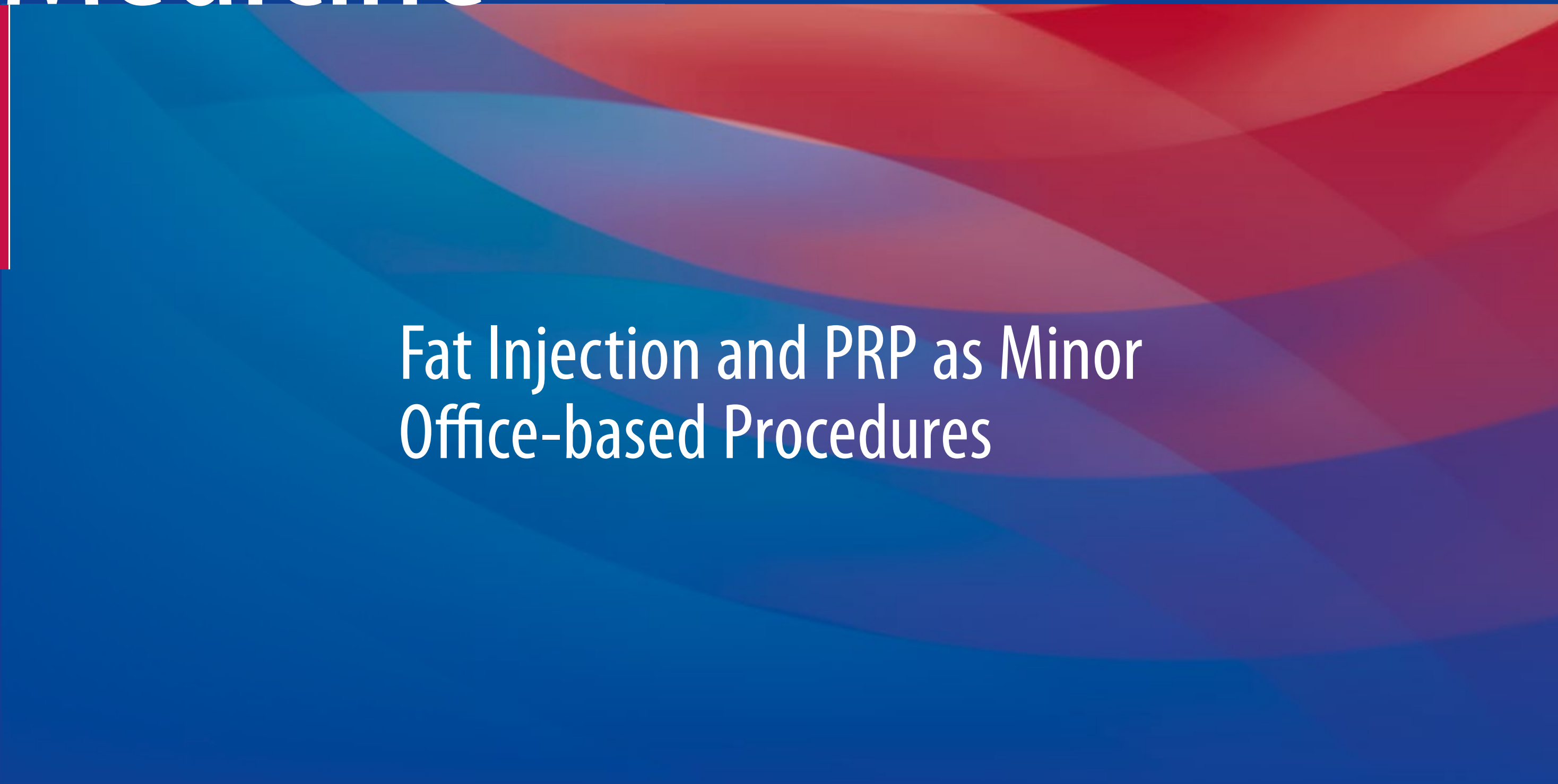

Fat Injection and PRP as Minor Office-based Procedures

Springer

Outpatient Regenerative Medicine

Mario Goisis
Editor

Outpatient Regenerative Medicine

Fat Injection and PRP as Minor Office-based Procedures

Springer

Editor
Mario Goisis
Maxillo-Facial and Aesthetic Surgeon
Go Easy Clinic
Milan
Italy

ISBN 978-3-319-44892-3 ISBN 978-3-319-44894-7 (eBook)
https://doi.org/10.1007/978-3-319-44894-7

Library of Congress Control Number: 2019933362

© Springer Nature Switzerland AG 2019
This work is subject to copyright. All rights are reserved by the Publisher, whether the whole or part of the material is concerned, specifically the rights of translation, reprinting, reuse of illustrations, recitation, broadcasting, reproduction on microfilms or in any other physical way, and transmission or information storage and retrieval, electronic adaptation, computer software, or by similar or dissimilar methodology now known or hereafter developed.
The use of general descriptive names, registered names, trademarks, service marks, etc. in this publication does not imply, even in the absence of a specific statement, that such names are exempt from the relevant protective laws and regulations and therefore free for general use.
The publisher, the authors, and the editors are safe to assume that the advice and information in this book are believed to be true and accurate at the date of publication. Neither the publisher nor the authors or the editors give a warranty, express or implied, with respect to the material contained herein or for any errors or omissions that may have been made. The publisher remains neutral with regard to jurisdictional claims in published maps and institutional affiliations.

This Springer imprint is published by the registered company Springer Nature Switzerland AG
The registered company address is: Gewerbestrasse 11, 6330 Cham, Switzerland

To my young assistants, Pietro and Matteo

Foreword

The gradual aging of the population and improved living conditions in many geographical areas have made regenerative medicine more and more relevant over the last few decades. Besides their traditional areas of application (e.g., reconstruction after trauma or injury), regenerative approaches have become increasingly more pertinent in antiaging or simply aesthetic medicine. The branches that avail themselves of regenerative approaches are numerous and include plastic surgery, odontostomatology, otolaryngology, orthopedics, dermatology, gynecology, and many others besides. The exponential increase of professionals, meetings, and training centers, together with strong links with the industrial world, has meant that the scientific level too of regenerative approaches has progressively reached high levels of excellence. The most advanced regenerative techniques emerging from research centers and supported by a wealth of first-class technologies are now being widely used in medicine. Regenerative techniques are based on three main pillars: stem-cells, growth factors, and scaffolds. The development of these, which may also be used in combination, is by no means simple and requires optimization by means of recourse to technologies that must be, at once, effective and safe while also being simple to carry out. Only the simplicity of the procedures involved can actually ensure their widespread use outside of operating theaters. Finally, we must remember that it is mandatory that all operators have a thorough and correct knowledge of the macroscopic and microscopic anatomy of the areas of the body which they intend treating. This aspect, above all, appears to be one of the prerequisites essential for correct treatment and achieving lasting results. All these considerations lead us to stress the need for the development of appropriate training courses capable of meeting the growing demands of a technologically highly advanced and rapidly evolving sector that is also making a huge contribution to the knowledge of the regenerative mechanisms of tissue.

Andrea Sbarbati
Department of Neuroscience, Biomedicine and Movement
Human Anatomy and Histology Section
University of Verona
Verona, Italy

Foreword

Surgery has always made use of fat grafts for reconstructive and aesthetic purposes. Starting from the early 1980s, the introduction of standardized techniques, like Coleman's, led to the achievement of excellent results reported in numerous scientific publications. So, today, many years after its first introduction, adipose tissue may be considered, without a shadow of doubt, the safest filler and the scientifically most validated medium of tissue regeneration. Today, the real challenge is to simplify and make harvesting and injection techniques more and more efficient. The future of lipofilling, by means of microfat and nanofat techniques, will most probably involve the integration and progressive replacement of injection techniques by hyaluronic acid and fillers.

Francesco Nicoletti
Multidisciplinary Department of Medical-Surgical
and Dental Specialties, Plastic Surgery Unit
Università degli Studi della Campania "Luigi Vanvitelli"
Naples, Italy

Contents

Part I General Aspects

Part II Aesthetic Medicine Step by Step

Part I

General Aspects

Introduction

1

Mario Goisis and Sara Izzo

The famous Pala di Brera (also known as the Montefeltro Altarpiece or Brera Altarpiece) was painted, using tempera on wood, in 1472–1474 by the Italian Renaissance master Piero della Francesca (Fig. 1.1). It is housed in one of Milan's the Pinacoteca di Brera, and was commissioned by Federico III da Montefeltro, Duke of Urbino, to celebrate his conquest of several castles.

Federico was a great "condottiero" (warlord or captain at arms) of the Renaissance, and is shown kneeling on the right-hand side of the painting. Piero portrayed the Duke in profile, a position recollective of coins and medals. His profile is one of the most famous in history, because of the empty space above the nose.

The reason was that during a tournament Federico was injured with a lance, losing his right eye. According to the legend, he uttered, "Never mind, I'll see better with one eye than with a hundred!" So, he decided to have the upper part of his nose cut away, in order to see better with his left eye. This might well be the first case of rhinoplasty we know about.

At the centre of the painting, hanging on a chain from the ceiling of the apse, is an egg, emblem of the promise of immortality and regeneration.

We like to think about regenerative medicine as the chain portrayed in the Pala di Brera.

In fact, during transfer of fat, injection of stem-cells and production of PRP, many different steps are required. For example, in the case of fat grafting we have to harvest the fat, process it, and, finally inject it into the recipient sites. These steps may be considered the four different links of a chain. Because a chain is only as strong as its weakest link, the creation of a procedure, optimal from start to finish, is mandatory.

Fig. 1.1 The Montefeltro Altarpiece or Brera Altarpiece. (Courtesy of the Pinacoteca di Brera Museum, Milan, Italy http://pinacotecabrera.org/)

In fact, if one link of the chain is weak, then all the procedures will be compromised. In the case of Piero's chain, the egg may fall. In the case of the transfer of fat, the fat cells will not survive and will not regenerate themselves in the recipient area.

M. Goisis (✉)
Department of Plastic Surgery, University of Campania "Luigi Vanvitelli", Naples, Naples, Italy

Maxillo-Facial and Aesthetic Surgeon, Go Easy Clinic, Milan, Italy

S. Izzo
Department of Plastic Surgery, University of Campania "Luigi Vanvitelli", Naples, Naples, Italy

M. Goisis (ed.), *Outpatient Regenerative Medicine*, https://doi.org/10.1007/978-3-319-44894-7_1

Fat Harvesting

2

Andrea Sbarbati, Giamaica Conti, Sara Izzo,
and Giovanni Francesco Nicoletti

2.1 Introduction

The fat grafting procedure may be divided into three separate phases: fat harvesting, fat processing, and fat injection into recipient sites [1]. When speaking of fat harvesting, we refer to the surgical procedure which permits us to obtain adipose tissue through the use of suction cannulas or, rarely, through en bloc surgical excision of fat. Processing techniques involve centrifugation, filtration, Telfa rolling, and cleansing of the fat to remove anaesthesia, oil, blood, and other components in the harvested adipose tissue. Injection techniques differ much, depending on the selection of different syringes and cannulas or needles for injecting the fat in the recipient area. Within each phase of fat grafting, there are many variations in techniques and numerous discussions in favour of one rather than another. It is mandatory to construct an optimal procedure from start to finish.

2.2 The Influence of the Size of Fat Particle

Fat particles may be defined as intact globules of adipocytes, interconnected by means of mesenchymal tissue. It should be noted that the structure of the individual fat particle does not occur naturally within the native tissue but is produced, rather, during the harvesting process. En bloc surgical excision of adipose tissue produces the largest fat particles.

In the case of liposuction by cannulas, the range of fat particles is directly related to the diameter of the cannula and the size of the cannula ports, with larger sizes separating larger particles. The theory that the size of adipose particles may have a direct influence on the survival of fat is described in many scientific studies.

In 1893, in Germany, Gustav Neuber described the transfer of lipoma specimens from the forearm to fill facial contour deficiencies produced by tuberculosis. He dissected fragments of fat from the abdomen in "bean or almond sizes." These fragments were reported to survive [2]. In 1937, Gurney reviewed fat transplants averaging 1.7 mm^3 over a period of 12 months and reported that "grafts were viable for at least 1 year" [3]. During the mid-1950s, Peer, in the journal *Plastic and Reconstructive Surgery* reported that "walnut sized fat grafts" seemed to have lost 45% of their original volume after 1 year, which may have been due to trauma during grafting, trimming, or to lack of blood supply [4].

Modern liposuction with a cannula was first described by Fischer and Fischer in Italy in 1974: this technique extended the success of fat grafting techniques significantly [5, 6]. Kato et al. recently published a pioneering study, emphasizing the significance of the size of fat particles in grafting. The authors demonstrated that within a particle, the adipocytes which survive are placed closer to the external part of the fat lobule. Based upon histological findings, fat particles may be divided into three different sections:

- Surviving section: the layer closest to the surface of the lobule. In this section all adipocytes survive.
- Regenerating section: the middle layer, where the adipocytes die but are replaced by proliferating stem-cells.
- Necrotic section: the central core of the fat particle, which presents with necrosis, oil cysts, and fibrosis.

The limits of the surviving and regenerating zones occurred normally at 100–300 μm and 600–1200 μm from the surface, respectively (Fig. 2.1).

A. Sbarbati (✉) · G. Conti
Department of Neuroscience, Biomedicine and Movement,
Human Anatomy and Histology Section, University of Verona,
Verona, Italy
e-mail: andrea.sbarbati@univr.it; giamaica.conti@univr.it

S. Izzo · G. F. Nicoletti
Department of Plastic Surgery,
University of Campania "Luigi Vanvitelli", Naples, Italy
e-mail: giovannif.nicoletti@unicampania.it

M. Goisis (ed.), *Outpatient Regenerative Medicine*, https://doi.org/10.1007/978-3-319-44894-7_2

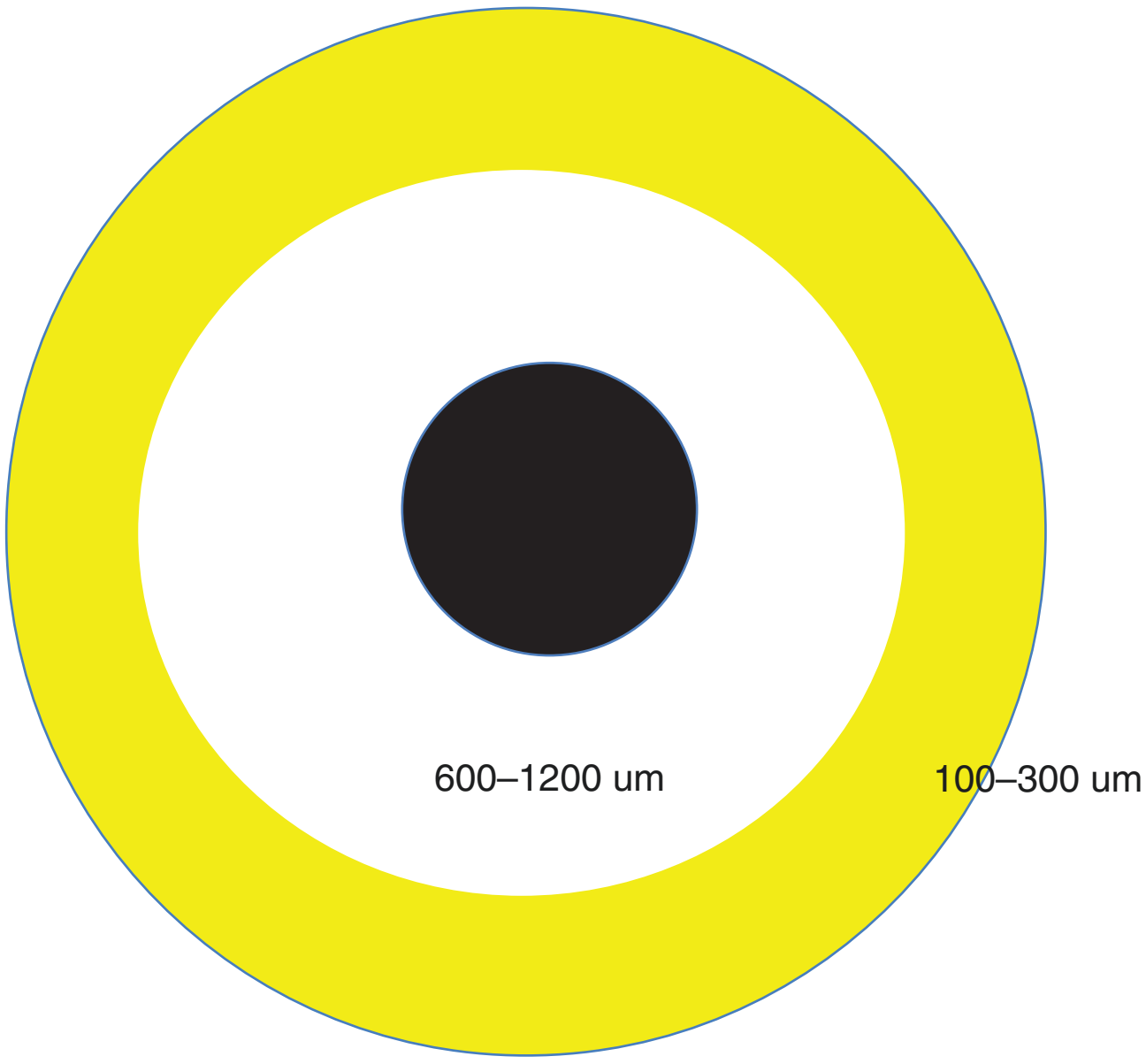

Fig. 2.1 Yellow: the surviving section 100–300 μm which is the layer closest to the surface where all the adipocytes survive. White: regenerating section 600–1200 μm which is the middle layer where the adipocytes die but are replaced by proliferating stem-cells. Black: the necrotic section, the central core of the fat particle dominated by necrosis, oil cysts, and fibrosis. (Published by kind permission of ©Mario Goisis 2018. All Rights Reserved)

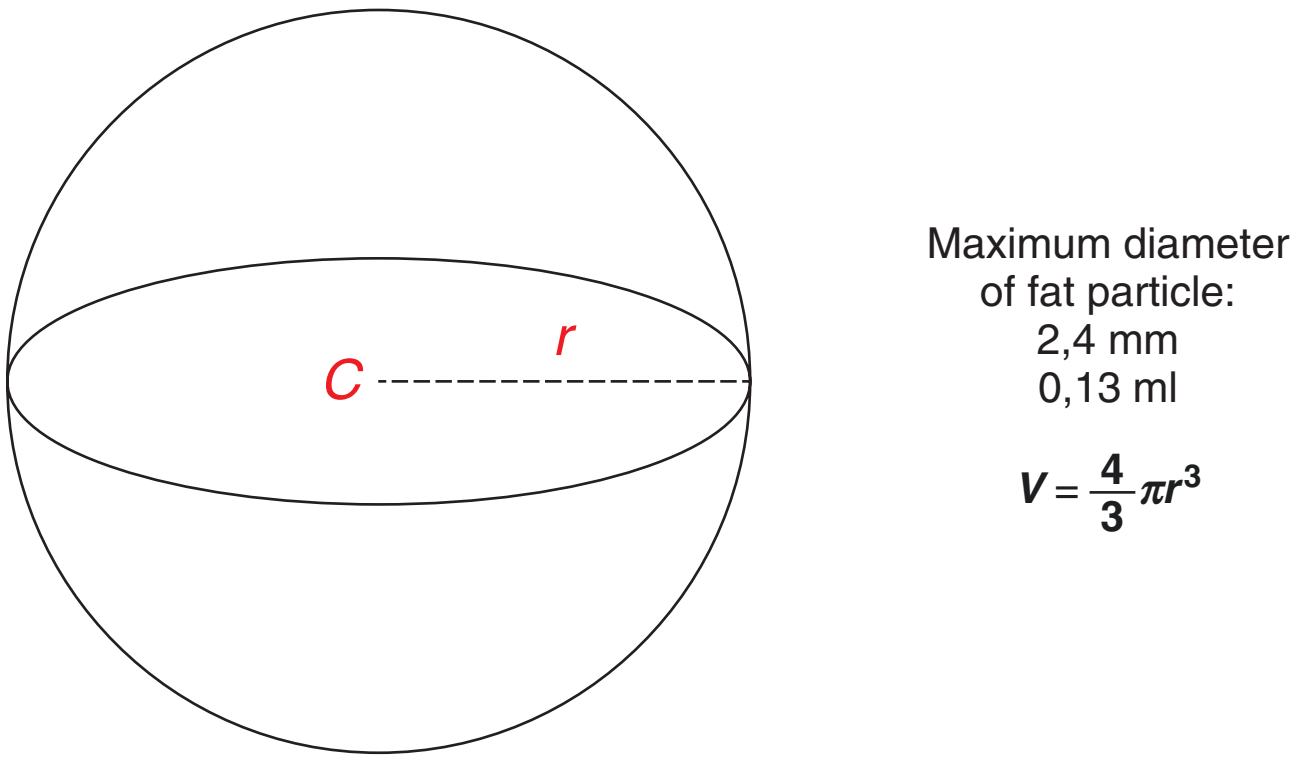

$$V = \frac{4}{3}\pi r^3$$

Fig. 2.2 Maximum diameter of a fat particle according to the limitations of diffusion described by Kato et al. (Published by kind permission of ©Mario Goisis 2018. All Rights Reserved)

Prior to the restoration of the blood supply, fat particles largely survive by diffusion of nutrients. As the diameter of adipose lobules becomes larger, the central zone of necrosis will ideally expand according to the limitations of diffusion (Fig. 2.2). Therefore, one may surmise that the size of fat particles may influence, ultimately, how much of the grafted fat survives [7].

2.3 Diameters of Cannulas and Port Sizes and Their Influence on Fat and Stem-Cell Viability

Shiffman and Mirrafati compared cannulas ranging from 2.5 to 3.7 mm in diameter, to establish if these an influenced cellular viability. They did not observe any significant difference [8]. When comparing a 2-mm- versus a 4-mm-diameter cannula, Leong et al. evaluated the state of the fat harvested. The study does not assert significant differences in metabolism [9]. According to Klein's definition, a micro-cannula has an inside diameter of 2.0 mm or less.

Trivisonno et al. studied whether the small size of a micro-cannula might reduce the collection of well-organized fat, which is mostly composed of mature adipocytes, and improve the harvesting of more superficial layers of adipose tissue, which are related to a higher percentage of ADSC. They compared (1) a rounded-tip cannula having a length of 170 mm, a diameter of 3 mm, and a single elliptic suction port on the side near its distal end (port diameter, 3 × 9 mm) and (2) a rounded-tip infiltration cannula having a length of 170 mm, a diameter of 2 mm, and 5 round ports positioned spirally along the sides of the distal cannula shaft (each port diameter, 1 mm).

Using the 3 mm cannula, they isolated nearly 1.4×10^5 cells/mL, a quantity similar to that described by several authors [10].

Fat harvested using a micro-cannula was associated with a higher number of stromal and vascular cells, and obtained a higher rate of survival. The main problem reported by Trivisonno et al. was related to the longer treatment times required for treatment using the micro-cannula compared to those needed when employing a standard cannula. In fact, aspiration of fat with a micro-cannula yielded smaller volumes of aspirated tissue with each stroke and, therefore, proved more time-consuming (approximately two times slower compared to manual suction with the larger cannula) [11].

Alharbi et al. [12] compared fat harvesting with the Coleman cannula (3 mm diameter, one-hole blunt tip) and fat harvesting using a 2 mm, multi-perforated hole blunt tip cannula. They used the different cannulas on contralateral areas of the same patients. The study established that growth-factor concentrations, cell-migration from pieces of fatty tissue, and adherence-rates of ASCs increased using the smaller cannula.

The authors concluded that these better results were due to the smaller sizes and different surface/volume ratios of pieces of the fatty tissue harvested with the smaller cannula.

2.4 A Newly-Patented Micro-Cannula

Goisis (Imcas 2015) described a newly-patented micro-cannula. This cannula has a small diameter (2 mm) with a blunt tip and six ports placed along the sides of the distal cannula shaft (each port is of a diameter of 1 mm). These ports are arranged in spirally with the angle of patency aligned along the axis of the cannula (Figs. 2.3 and 2.4). The ports have a rectangular shape, with a raised edge arranged parallel to the axis of the cannula and a depressed edge placed in front of the raised edge.

The main advantages of a cannula designed in such a way are related to faster times of treatment compared with those of other micro-cannulas: the aspiration of fat is performed with a rotational movement (see Figs. 2.5, 2.6, and 2.7). The

Fig. 2.3 The design of the cannula (published by kind permission of ©Mario Goisis 2018. All Rights Reserved)

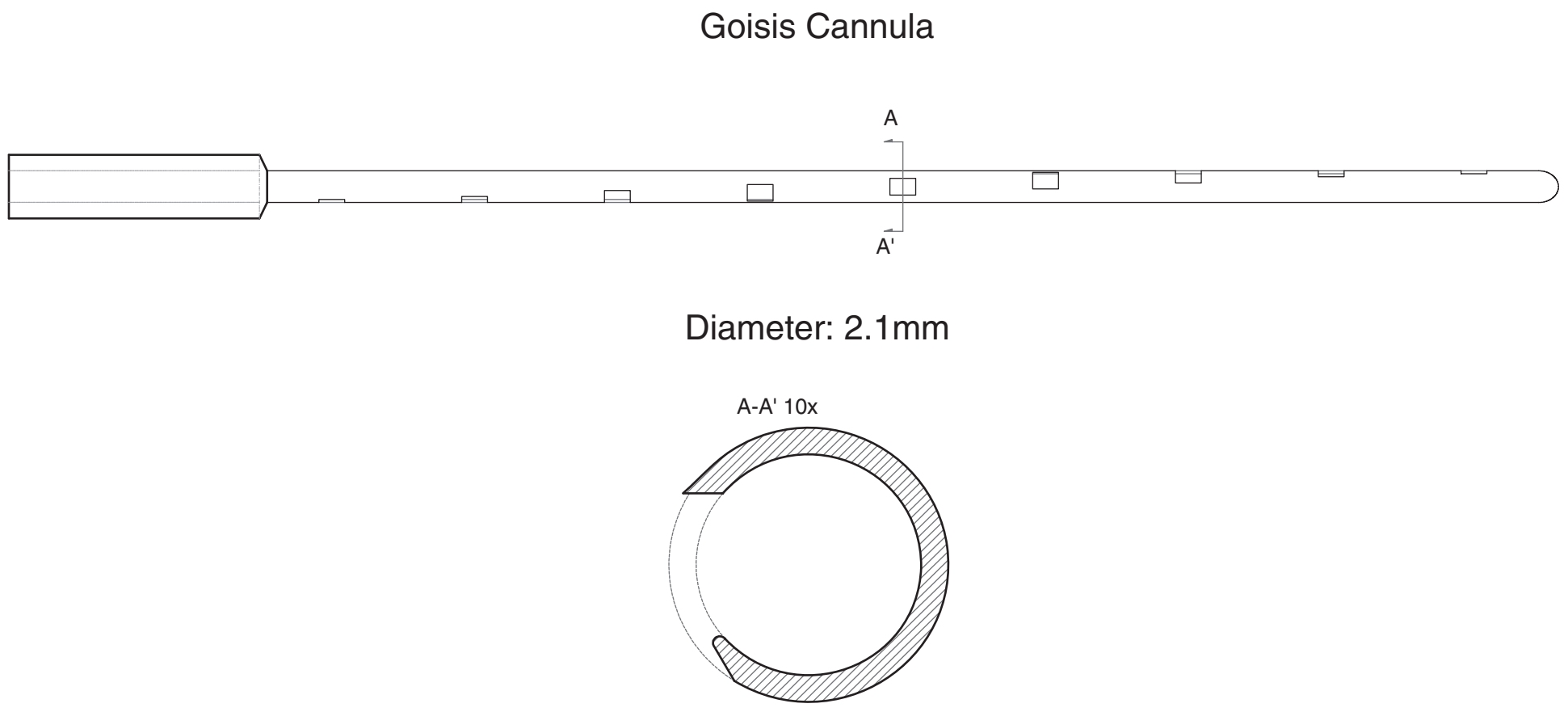

Fig. 2.4 The suction ports are arranged spirally

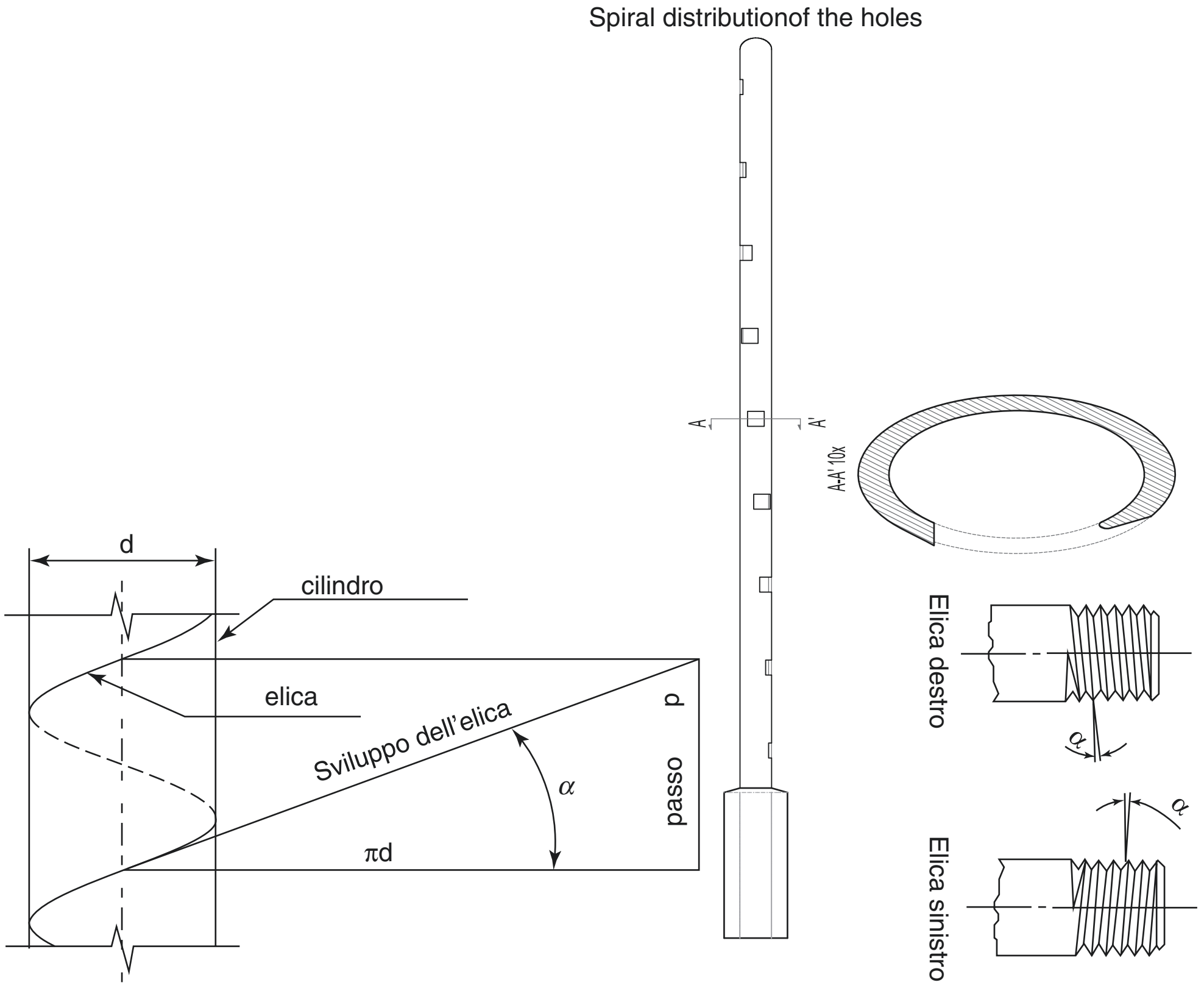

Fig. 2.5 The particularity of the rotational movement to be performed to harvest the fat. The rotational movement, which increases fat harvesting, is efficient, thanks to the depressed edge of the port holes, which facilitates the entrance of the fat into the cannula. Furthermore, the raised-barbed edge at the front of the depressed edge increases dissection of fat tissue and better aspiration of adipocytes. (Published by kind permission of ©Mario Goisis 2018. All Rights Reserved)

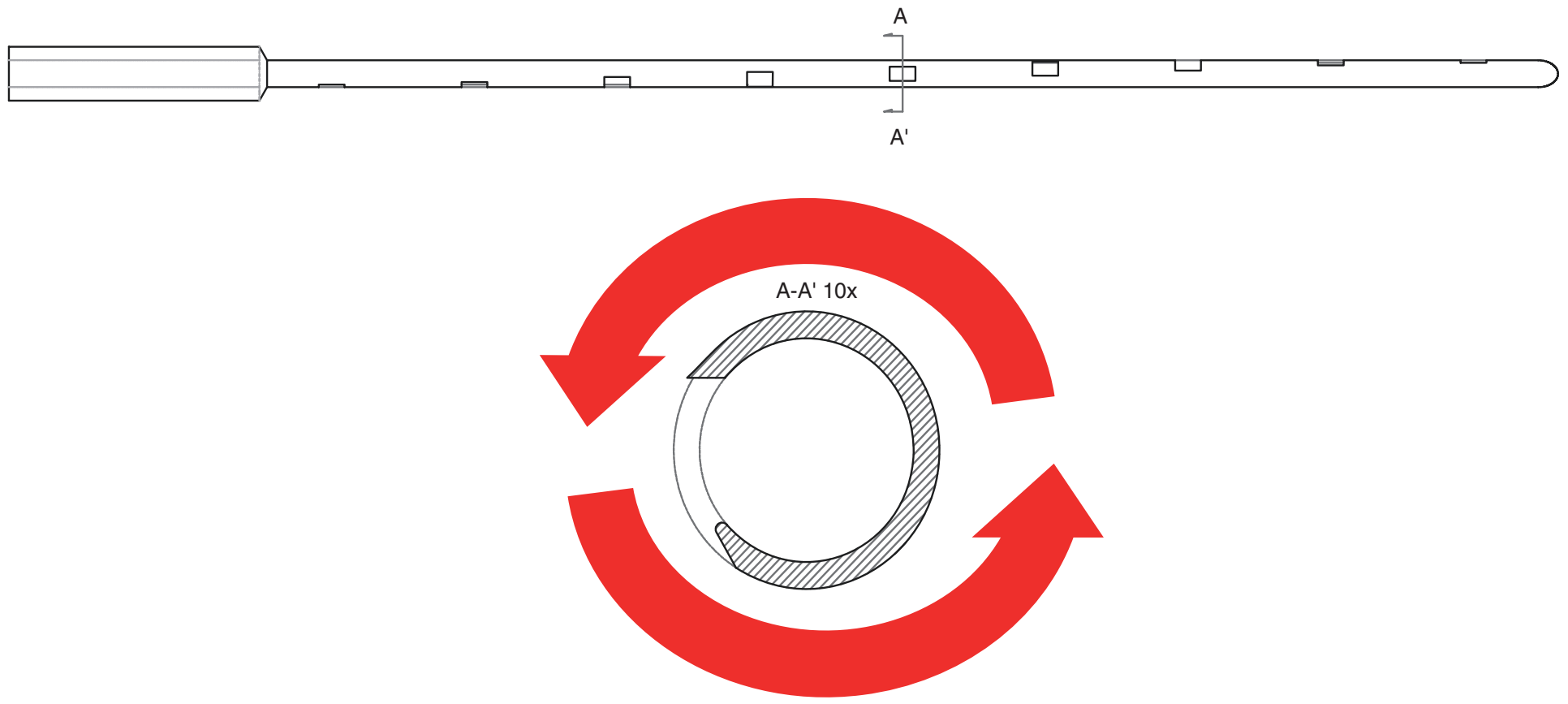

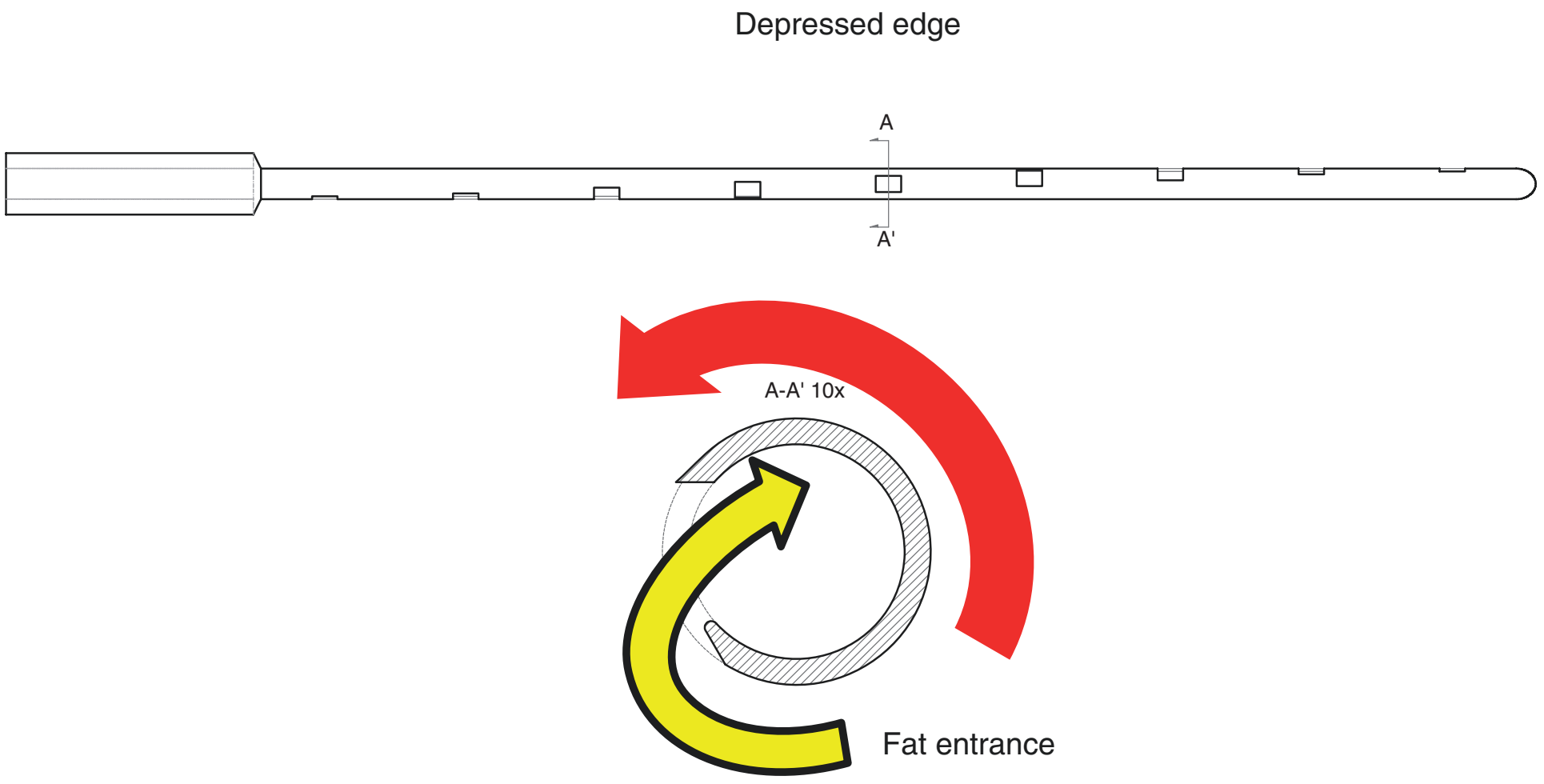

Fig. 2.6 The depressed edge of the holes increases the entrance of the fat into the cannula. (Published by kind permission of ©Mario Goisis 2018. All Rights Reserved)

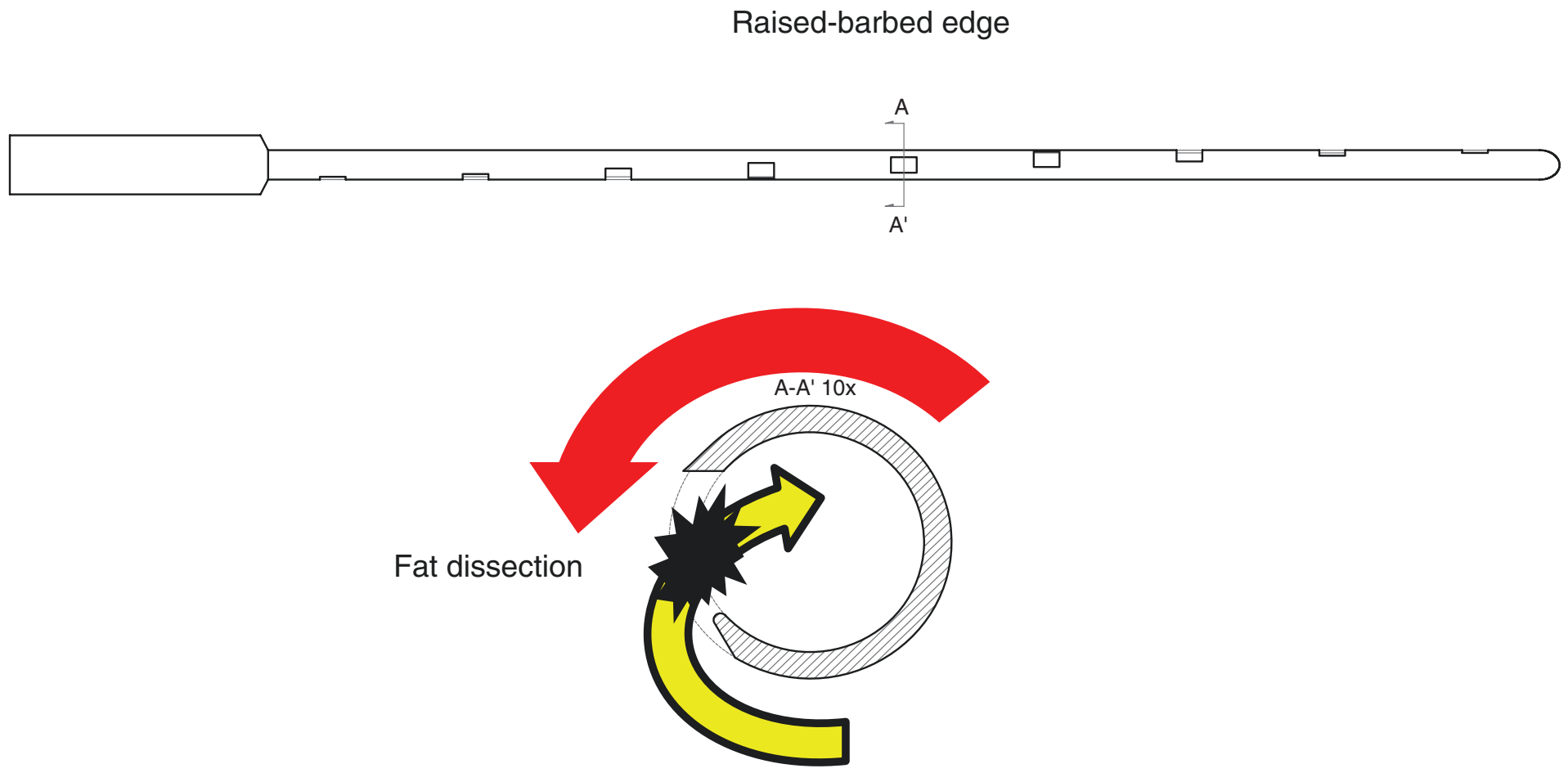

Fig. 2.7 The raised-barbed edge at the front of the depressed edge increases dissection of fat tissue, with better aspiration of adipocytes. (Published by kind permission of ©Mario Goisis 2018. All Rights Reserved)

depressed edge promotes the entrance of fat into the hole. The raised edge facilitates the dissection of the fat particles. This way, the shape of the multiple ports yields a large volume of aspirated tissue with each rotational stroke. The use of the Goisis cannula is, therefore, several times more efficient compared to the Coleman harvesting cannula (approximately twice as fast as the Coleman 3-mm cannula).

Histological examinations performed on 547 samples demonstrated that the fat cells harvested with the Goisis cannula were associated with a higher number of stromal and vascular components, when compared with fat harvested using the traditional Coleman (Figs. 2.8, 2.9, 2.10, and 2.11). The quality of the aspirate is finer, thus lending itself to lipofilling procedures using a small cannula for infiltration to the donor site. The micro-cannula reduces incidences of patient trauma, discomfort, and skin irregularities and minimises the risk of vascular injury due to multiple reduced-size ports. Because the insertion requires less force and is more precise, the micro-cannula affords superior manual control, improved superficial removal of fat (reducing the risk of accidental injuries to deeper tissues), and fewer scars due to the micro-incisions required.In a Study presented by Goisis et al. Imcas 2019 (Goisis et al., comparing protocols, IMCAS 2019) the role of Goisis cannula is stem-cells viability was discussed.

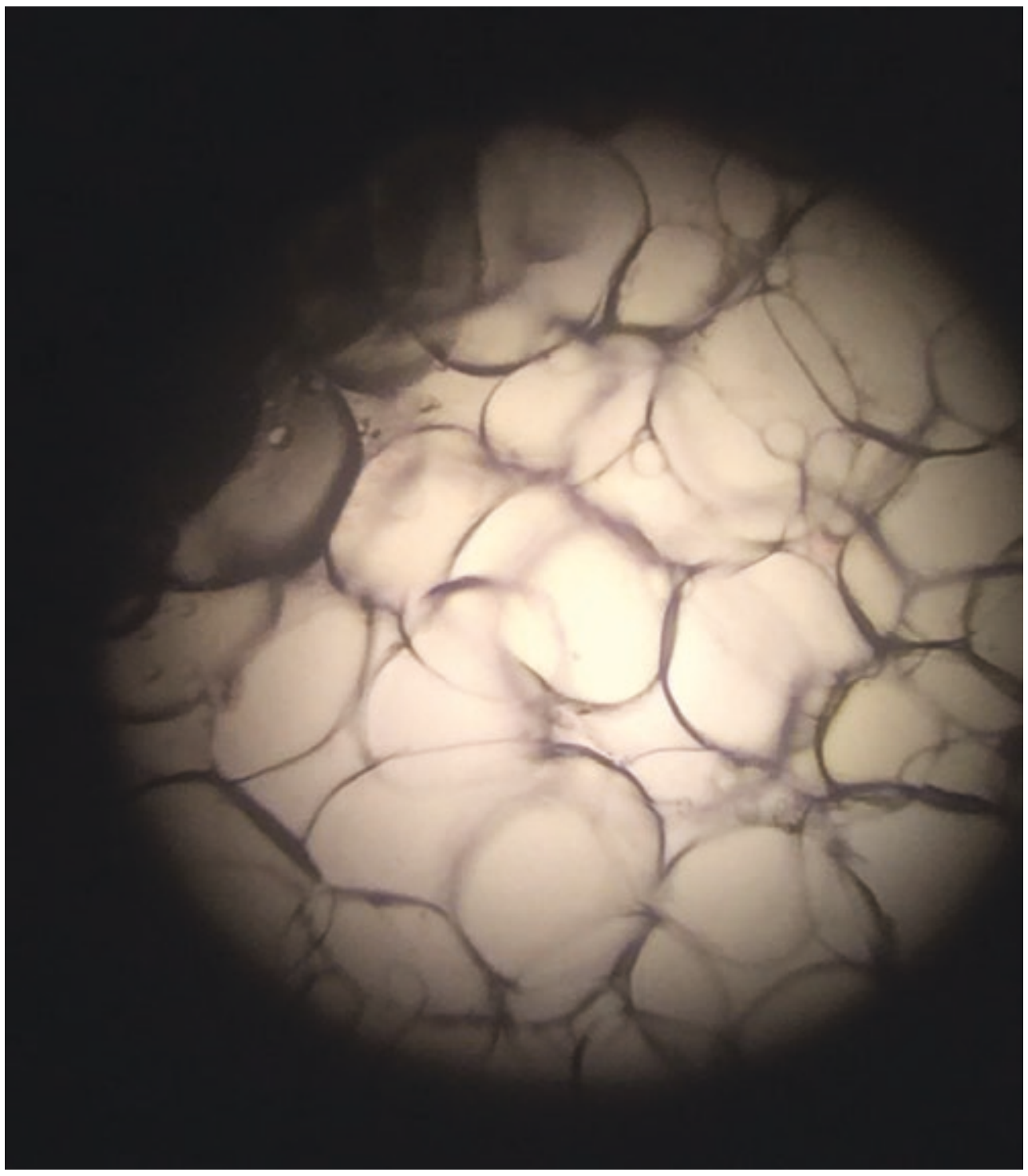

Fig. 2.8 Histological examination of fat harvested by a Goisis cannula. The adipocytes are well preserved. (Published by kind permission of ©Mario Goisis 2018. All Rights Reserved)

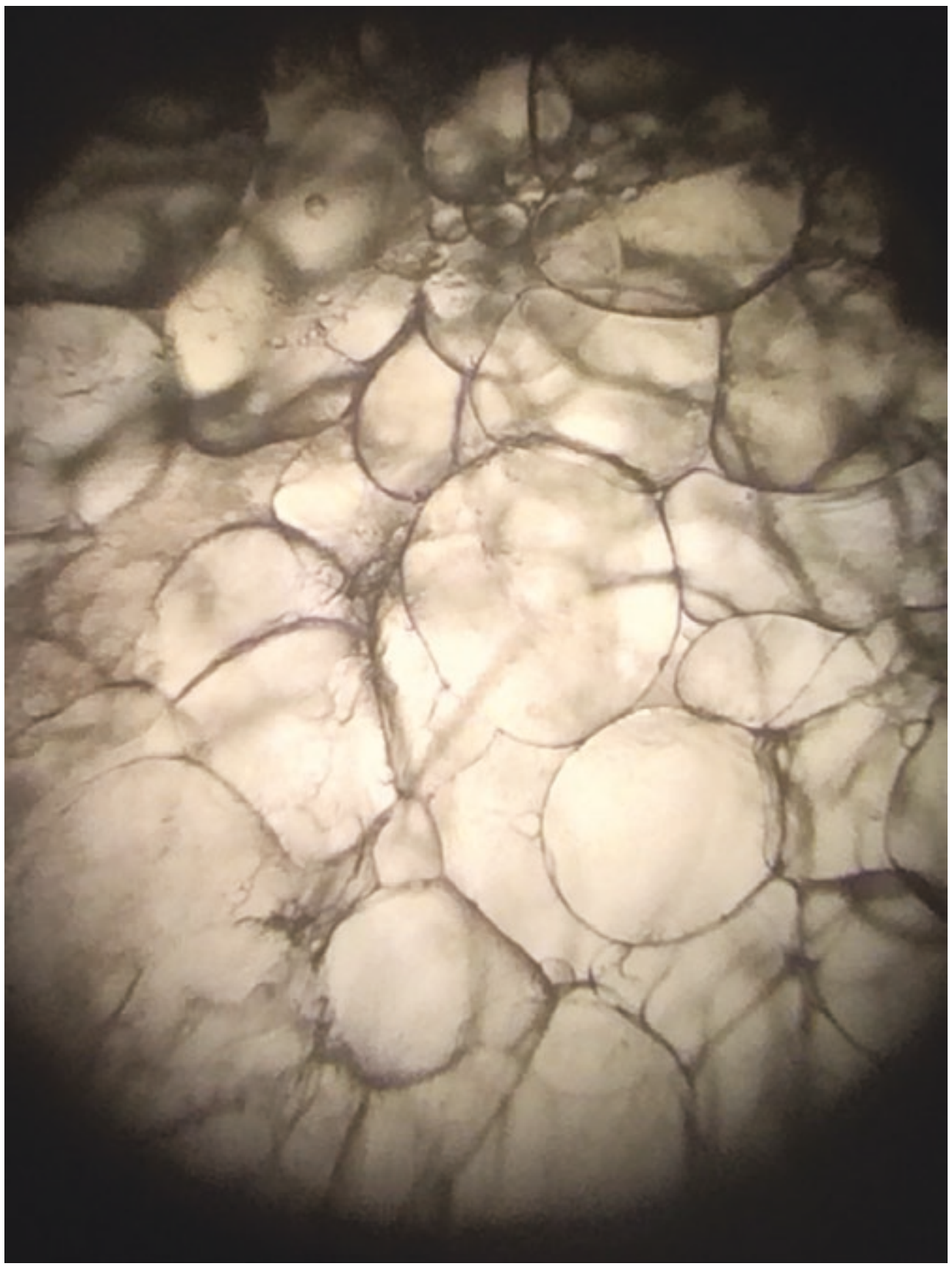

Fig. 2.9 Histological examination of fat harvested using a single-hole cannula. The adipocytes are less well preserved. (Published by kind permission of ©Mario Goisis 2018. All Rights Reserved)

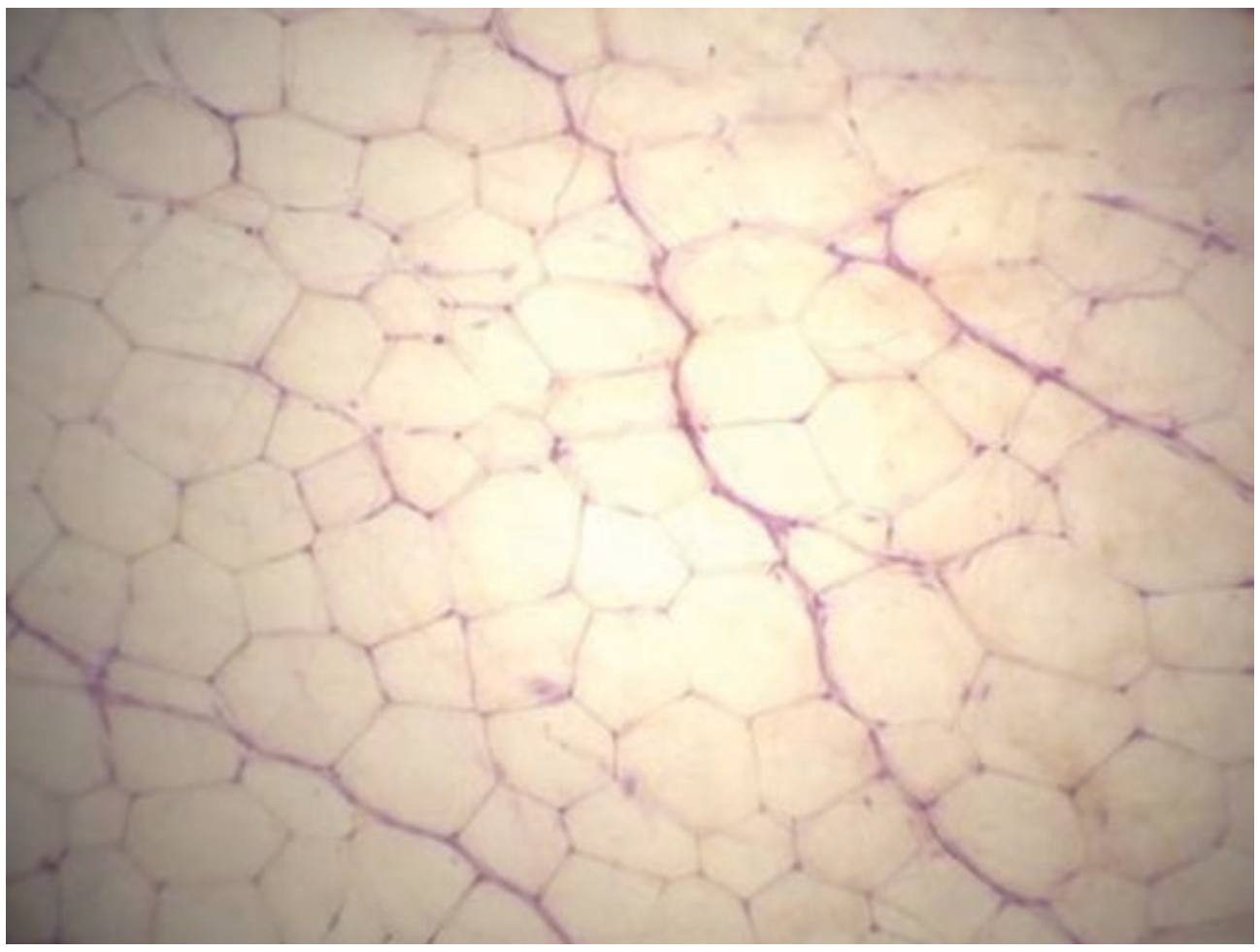

Fig. 2.10 Histological examinations of fat cells harvested using a Goisis cannula. (Published by kind permission of ©Mario Goisis 2018. All Rights Reserved)

Fig. 2.11 (**a, b**) Fat harvested with Goisis cannula is associated with a higher number of stromal and vascular components when compared with fat harvested using a single-hole cannula. (Published by kind permission of ©Mario Goisis 2018. All Rights Reserved)

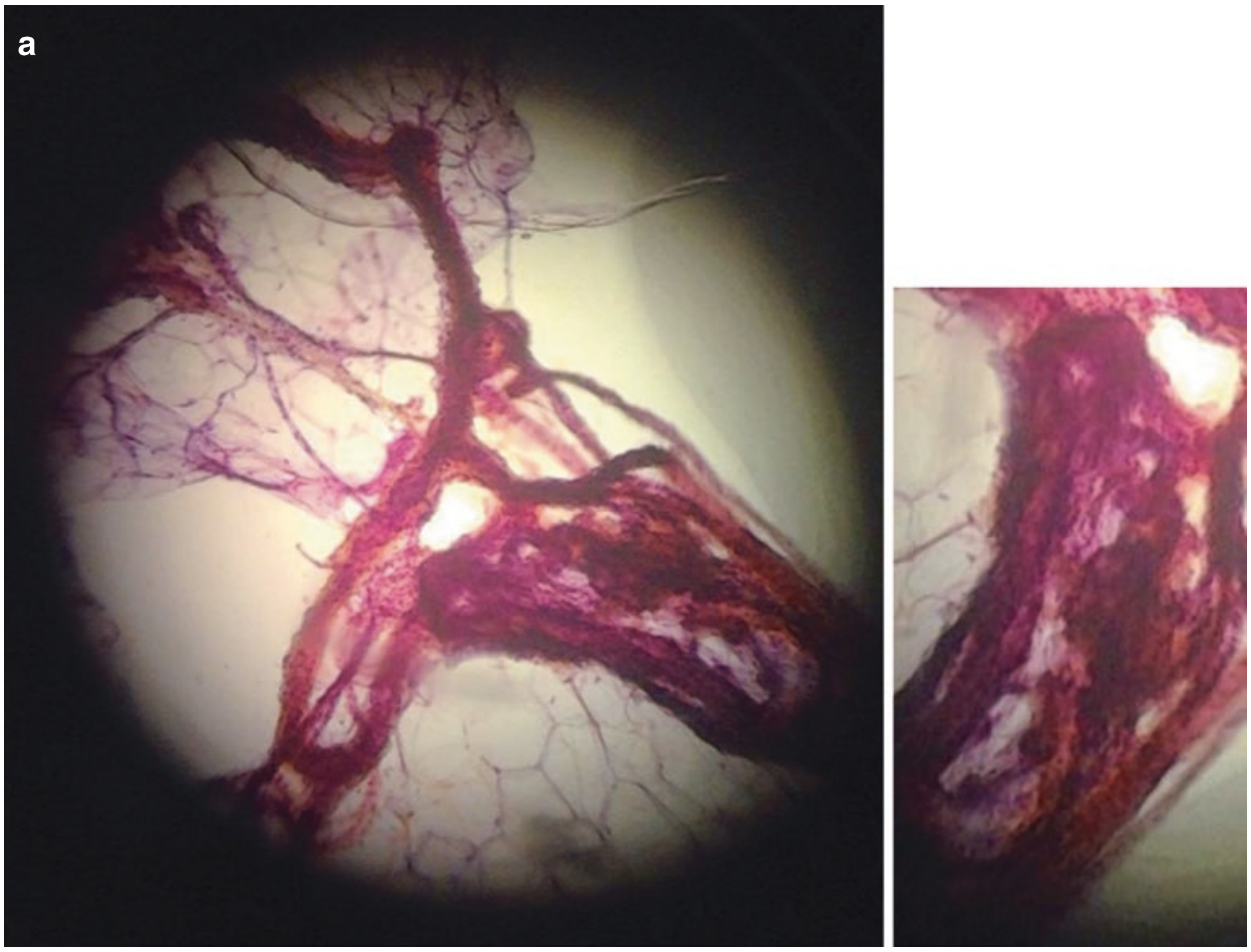

Fig. 2.11 (continued)

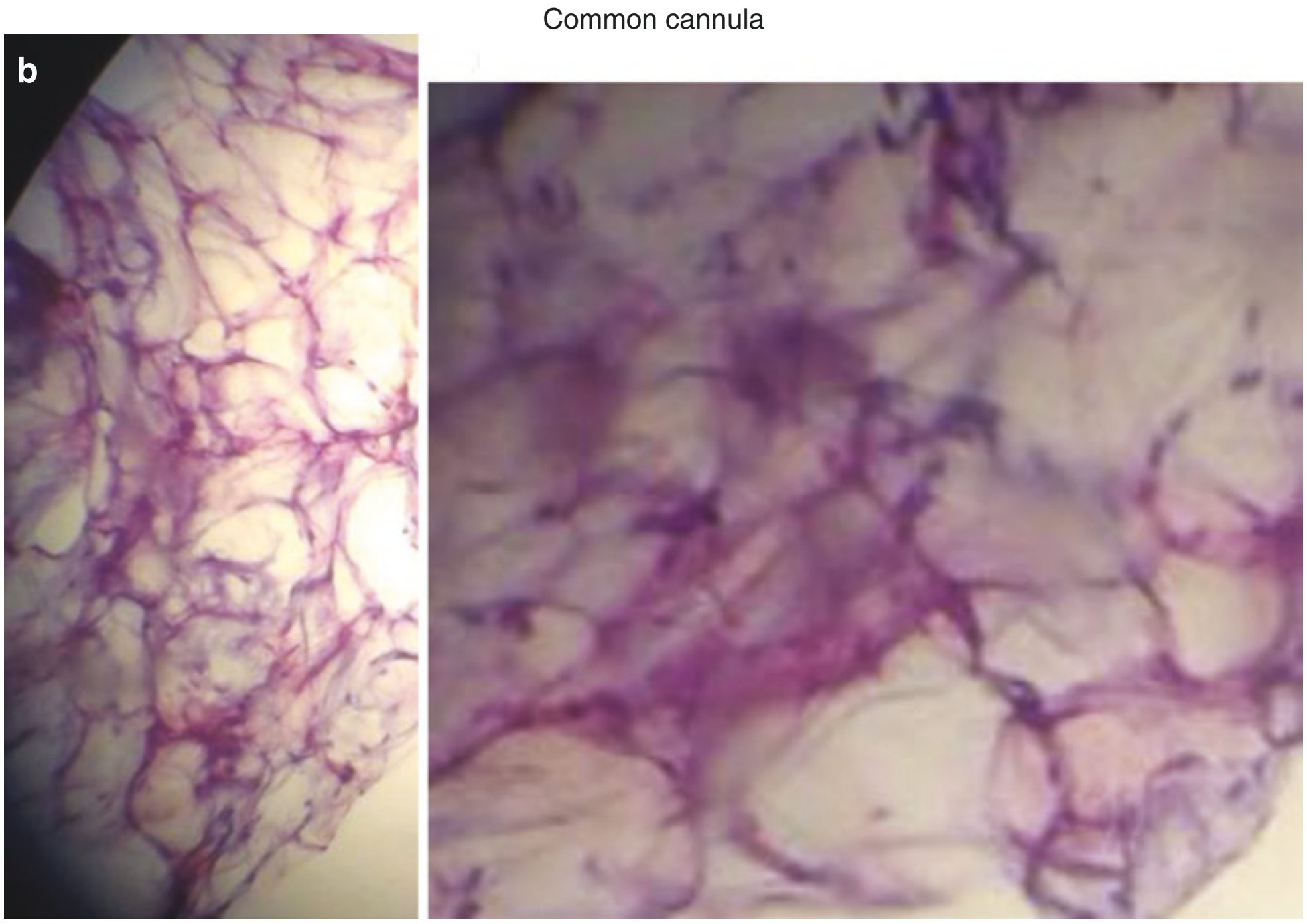

Table 2.1 The number of stem-cell of 2 different samples was measured at 72 hours, 7 days and 14 days after colture.In Blu fat harvested with Coleman canula, in orange microfat harvested with goisis cannula

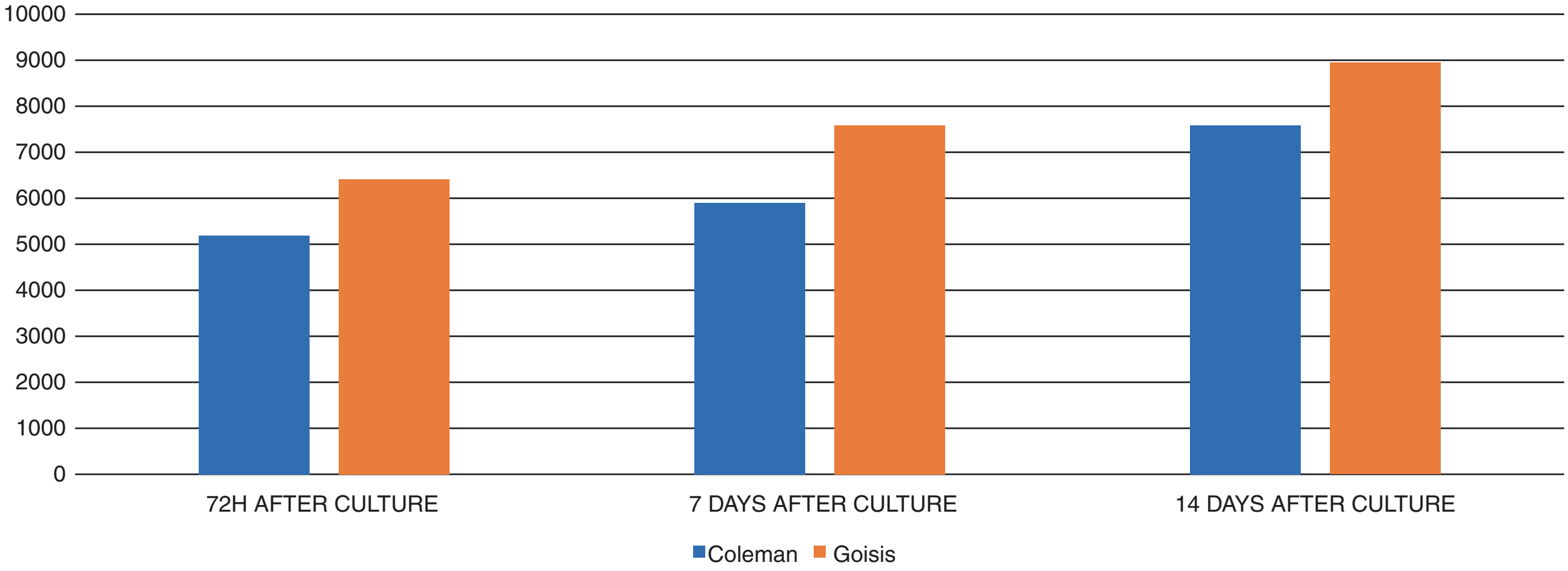

The number of stem-cell of 2 different samples was measured at 72 hours, 7 days and 14 days after colture. The first sample was harvested with Goisis Cannula, with high values of stem-cells. The second sample was harvested with Coleman cannula with lower levels of stem-cells (Table 2.1).

2.5 The Effect of Negative Pressure Upon Fat and Stem-Cell Viability

Shiffman and Mirrafati compared suction pressures to establish their effect on cellular survival. The significant result was that greater cellular damage corresponded with a vacuum pressure in excess of 700 mmHg [8].

In the study by Cheriyan et al., adipose viability was 47% higher after aspiration at low pressure (−250 mmHg) compared with aspiration at high negative pressure (−760 mmHg). In addition, cell survival at 7 days was significantly higher with low-pressure aspiration [13]. This observation was confirmed by Nguyen et al. who proved that only 10% of the cells survived after liposuction at 760 mmHg [14].

Mojallal et al. evaluated the effect of pressure on the harvest of stromal vascular fraction (SVF) cells. Five different harvesting techniques were tested: pump suction at −350, pump suction at −700 mmHg, and power-assisted liposuction at −350 and −700 mmHg. Cell harvest with a pressure of −350 mmHg, assisted or not, was greater than that obtained at −700 mmHg. The conclusion was that −700 mmHg decreases the number of SVF cells harvested [15].

References

1. Gause T, Kling R, Sivak W, Marra K, Rubin J, Kokai L. Particle size in fat graft retention: a review on the impact of harvesting techniques in surgical lipofilling outcomes. Adipocyte. 2014;3(4):273–9.
2. Neuber G. Fettransplantation. Chir Kongr Verhandl Dsch Gesellch Chir. 1893;22:66.
3. Gurney CE. Experimental study of the behavior of free fat transplants. Surgery. 1937;3:679–92.
4. Peer A. The neglected free fat graft. Plast Reconstr Surg. 1956;18:233–50.
5. Fournier P. Liposculpture: the syringe technique. Paris: Arnette Blackwell; 1991. p. 265–6.
6. Illouz YG. The fat cell “graft”: a new technique to fill depressions. Plast Reconstr Surg. 1986;78:122–3.
7. Kato H, Mineda K, Eto H, Doi K, Kuno S, Kinoshita K, Kanayama K, Yoshimura K. Degeneration, regeneration, and cicatrization after fat grafting: dynamic total tissue remodeling during the first 3 months. Plast Reconstr Surg. 2014;133:303e–13e.
8. Shiffman MA, Mirrafati S. Fat transfer techniques: the effect of harvest and transfer methods on adipocyte viability and review of the literature. Dermatol Surg. 2001;27:819–26.
9. Leong DT, Hutmacher DW, Chew FT, Lim T-C. Viability and adipogenic potential of human adipose tissue processed cell population obtained from pump-assisted and syringe-assisted liposuction. J Dermatol Sci. 2005;37:169–76.
10. Harris LJ, Zhang P, Abdollahi H, et al. Availability of adipose-derived stem cells in patients undergoing vascular surgical procedures. J Surg Res. 2010;163:e105–12.
11. Farr ST, Trivisonno A. Differential fat harvesting. Plast Aesthet Res. 2014;1:103–7.
12. Alharbi Z, Opländer C, Almakadi S. Conventional vs. micro-fat harvesting: how fat harvesting technique affects tissue-engineering approaches using adipose tissue-derived stem/stromal cells. J Plast Reconstr Aesthet Surg. 2013;66:1271–8.
13. Cheriyan T, Kao HK, Qiao X, Guo L. Plast Reconstr Surg. 2014;133(6):1365–8.
14. Nguyen P, Desouches C, Gay A, Hautier A, Magalon G. Development of micro-injection as an innovative autologous fat graft technique: the use of adipose tissue as dermal filler. J Plast Reconstr Aesthet Surg. 2012;65:1692–9.
15. Mojallal A, Auxenfans C, Lequeux C, Braye F, Damour O. Influence of negative pressure when harvesting adipose tissue on cell yield of the stromal-vascular fraction. Biomed Mater Eng. 2008;18(4-5):193–7.

3

Fat Harvesting Step by Step

Mario Goisis and Sara Izzo

3.1 Microfat Preparation: Harvesting in the Hip-Pelvis Area

Before providing a step-by-step description of the procedure, it is useful to recall some of the basic elements of the anatomy of the hip. The pelvic skeleton is formed, to the front, by the sacrum and the coccyx bones and by a pair of hip-bones to the left and right. The two hip-bones connect the lower limbs to the spine, while the lower limbs are connected to each other anteriorly and attached to the sacrum posteriorly.

Each hip-bone comprises three sections: the ilium, the ischium, and the pubis. The name of the ilium comes from the Latin word *ile* or *ilis*, meaning "groin" or "flank". The ilium is the largest of the coxal bones (Figs. 3.1 and 3.2).

The iliac crest is the upper border of the wing of the ilium (Fig. 3.3, green points). Palpable along its entire length, the crest is situated between the anterior superior iliac spine (ASIS) (Fig. 3.3, red point) and the posterior superior iliac spine (PSIS) (Fig. 3.4). The anterior superior iliac spine (ASIS) is a bony projection of the iliac bone and an important landmark of surface anatomy. It refers to the anterior extremity of the iliac crest of the pelvis, which provides an anchor for the inguinal ligament and the sartorius muscle (Figs. 3.5, 3.6, 3.7, 3.8, 3.9, and 3.10).

3.2 Low-Pressure Microfat Aspiration: Materials and Methods

Microfat harvesting can be carried out in a small operating thetare/medical practice. Oxygen, pulse oximetry, and a crash cart/box should be present. A standard procedure microfat box is used (Courtesy of Microfat.com) (Fig. 3.11). The microfat box is composed of some single-use elements: a ramp with a closed system for washing and filtration, 4 60-cc syringes, 2 10-cc syringes, one 1-cc syringe, a 30-gauge needle, a 16-gauge needle, a 21-gauge needle, and a 22-gauge 4-cm blunt cannula.

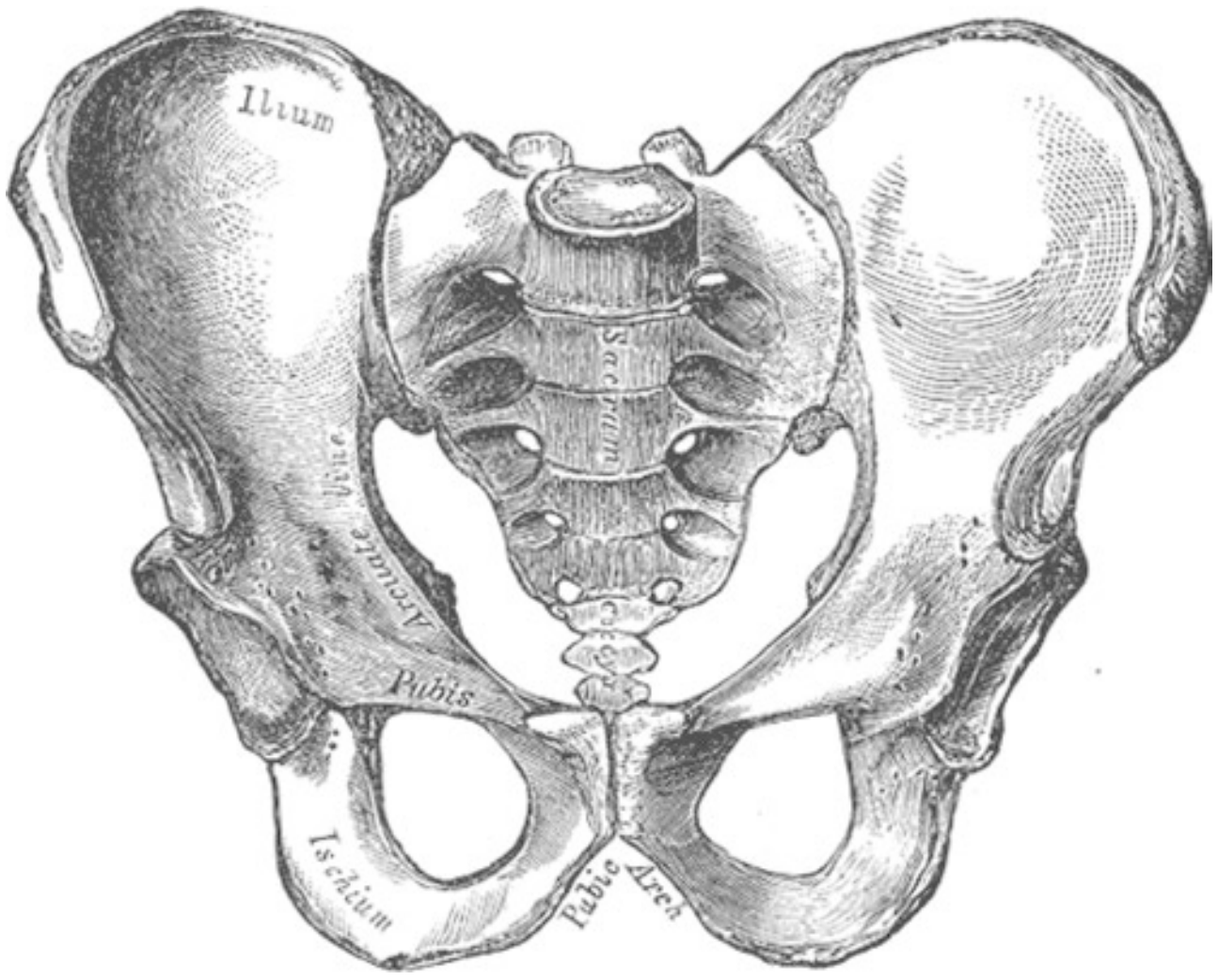

Fig. 3.1 The ilium is the largest of the coxal bones (reproduced from Gray's Anatomy, 20th edition, 1918, under public domain). (Published by kind permission of ©Mario Goisis 2018. All Rights Reserved)

This microfat box can be used in conjunction with some autoclavable elements, in particular the microfat tray (Fig. 3.12, Published by kind permission of ©Mario Goisis 2018. All Rights Reserved) and the autoclavable 10-cm Goisis cannula (Microfat or Tulip). The Goisis tray is composed of a plastic support for the ramp and of two trays for the Klein and

M. Goisis (✉)
Maxillo-Facial and Aesthetic Surgeon, Go Easy Clinic, Milan, Italy

S. Izzo
Department of Plastic Surgery, University of Campania "Luigi Vanvitelli", Piazza Miraglia, Milan, 80138, Italy

M. Goisis (ed.), *Outpatient Regenerative Medicine*, https://doi.org/10.1007/978-3-319-44894-7_3

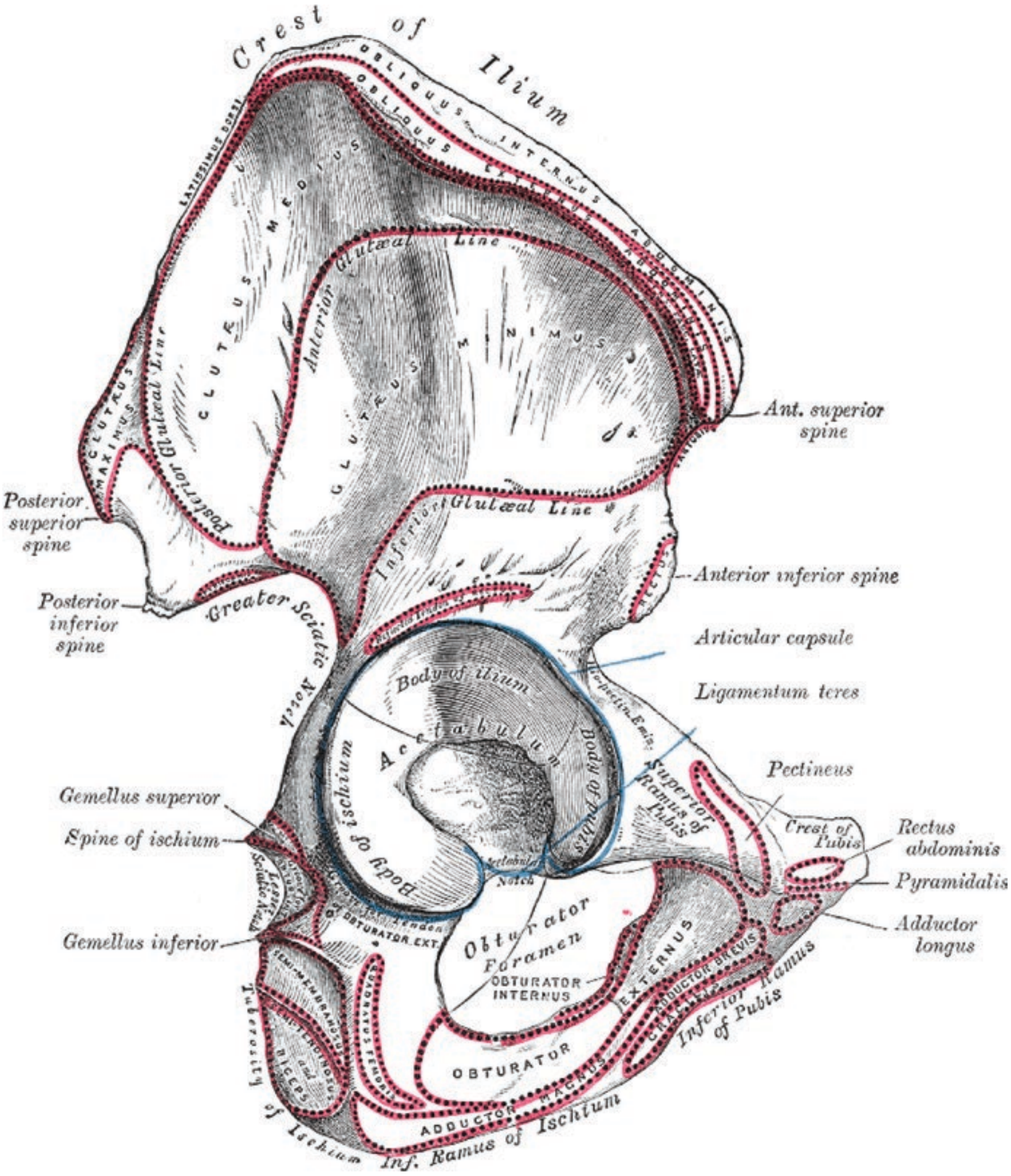

Fig. 3.2 The ilium is the largest of the coxal bones (reproduced from Gray's Anatomy, 20th edition, 1918, under public domain). (Published by kind permission of ©Mario Goisis 2018. All Rights Reserved)

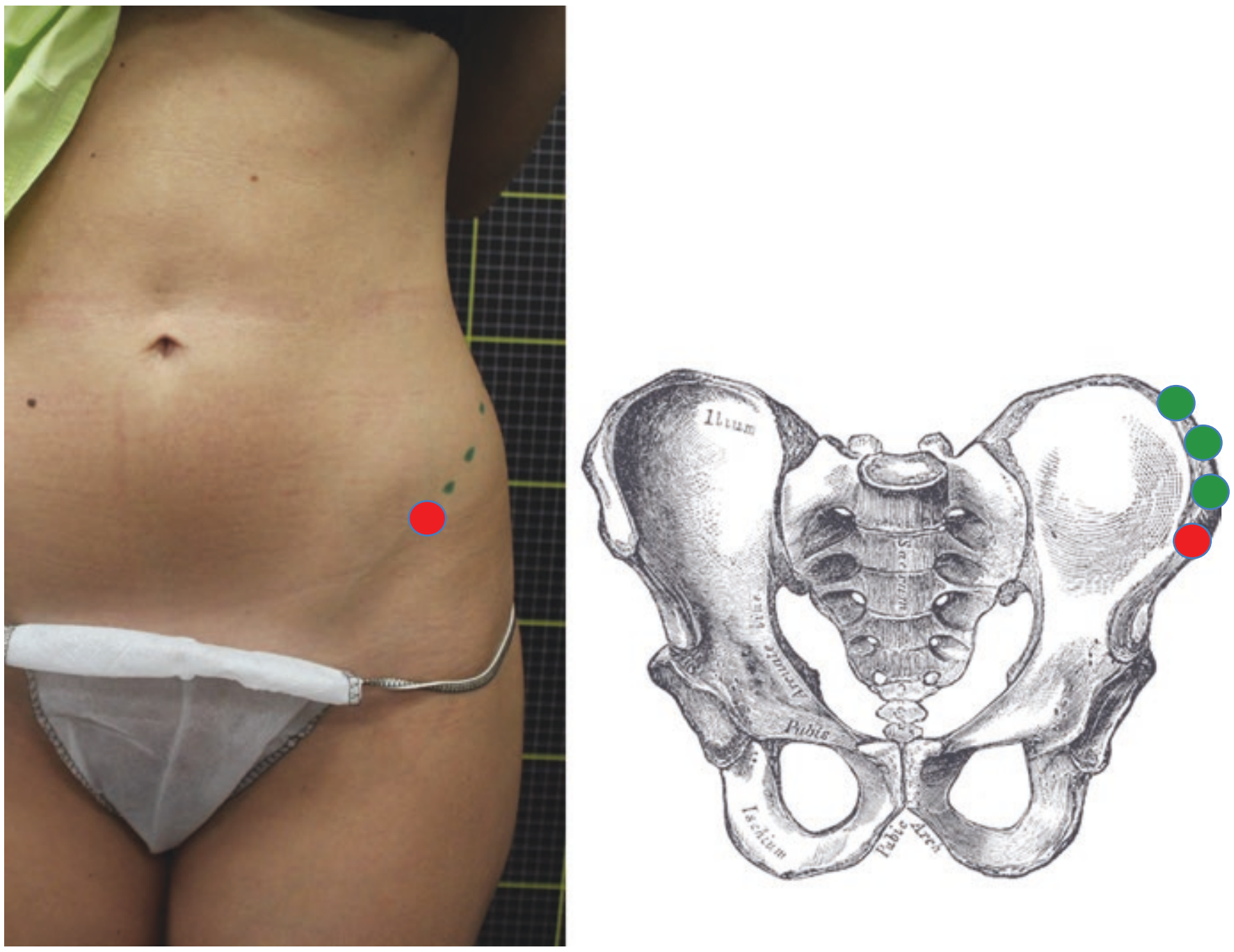

Fig. 3.3 The iliac crest is the upper border of the wing of ilium (green points). It is palpable along its entire length. The crest is situated between the anterior superior iliac spine (ASIS) (Fig. 3.3, red point) and the posterior superior iliac spine (PSIS) (Fig. 3.4). (Published by kind permission of ©Mario Goisis 2018. All Rights Reserved)

Fig. 3.4 The iliac crest is the superior border of the wing of ilium (green points). It is palpable along its entire length. The crest is included between the anterior superior iliac spine (ASIS) (Fig. 3.3, red point) and the posterior superior iliac spine (PSIS) (Fig. 3.4). (Published by kind permission of ©Mario Goisis 2018. All Rights Reserved)

Fig. 3.5 Anatomical dissection of the harvesting area. The subcutaneous plane is exposed. (Published by kind permission of ©Mario Goisis 2018. All Rights Reserved)

Fig. 3.6 An ultrasound image of the harvesting area. The red spot appears in correspondence to the anterior superior iliac spine. The use of ultrasound in thin patients can be supported by measuring the thickness of the adipose tissue in the aspiration site considered for harvesting and seeking the optimal position to prepare for the procedure. Ultrasound assistance may be considered for the initial learning curve or in thin patients. (Published by kind permission of ©Mario Goisis 2018. All Rights Reserved)

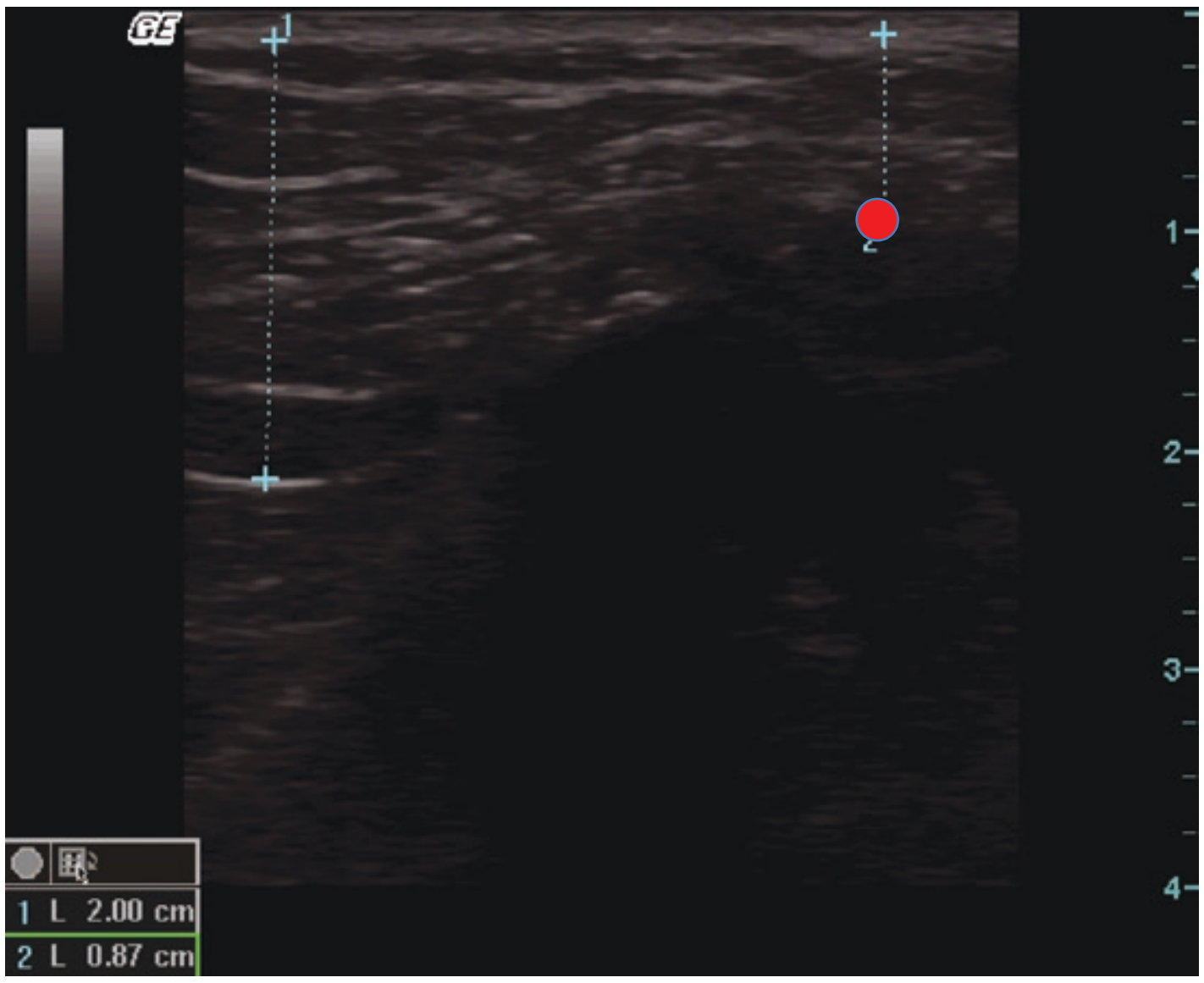

Fig. 3.7 Marking the harvesting area: the entry-point is signed in correspondence to the anterior superior iliac spine (ASIS). The flank fat pad is pinched and marked. (Published by kind permission of ©Mario Goisis 2018. All Rights Reserved)

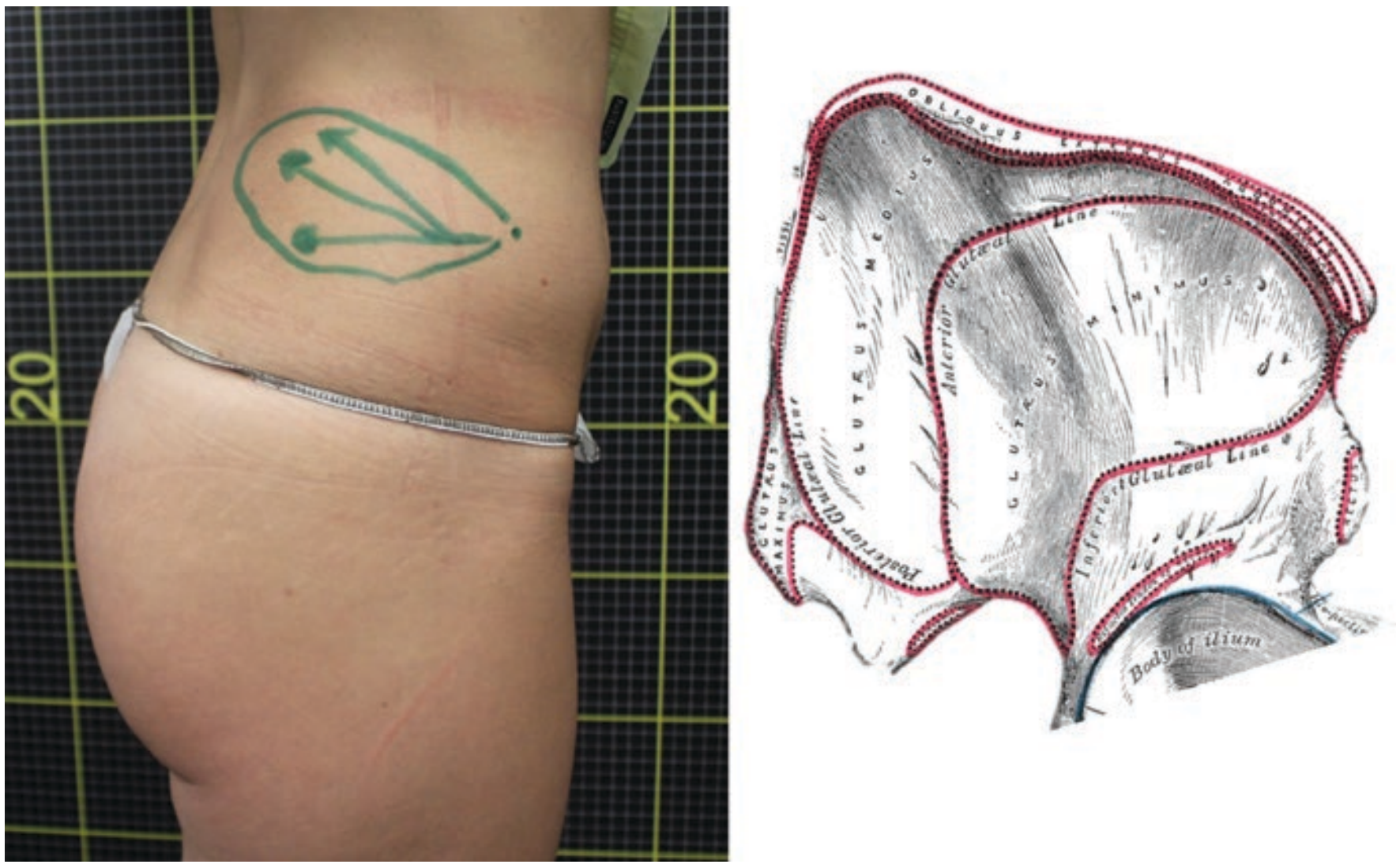

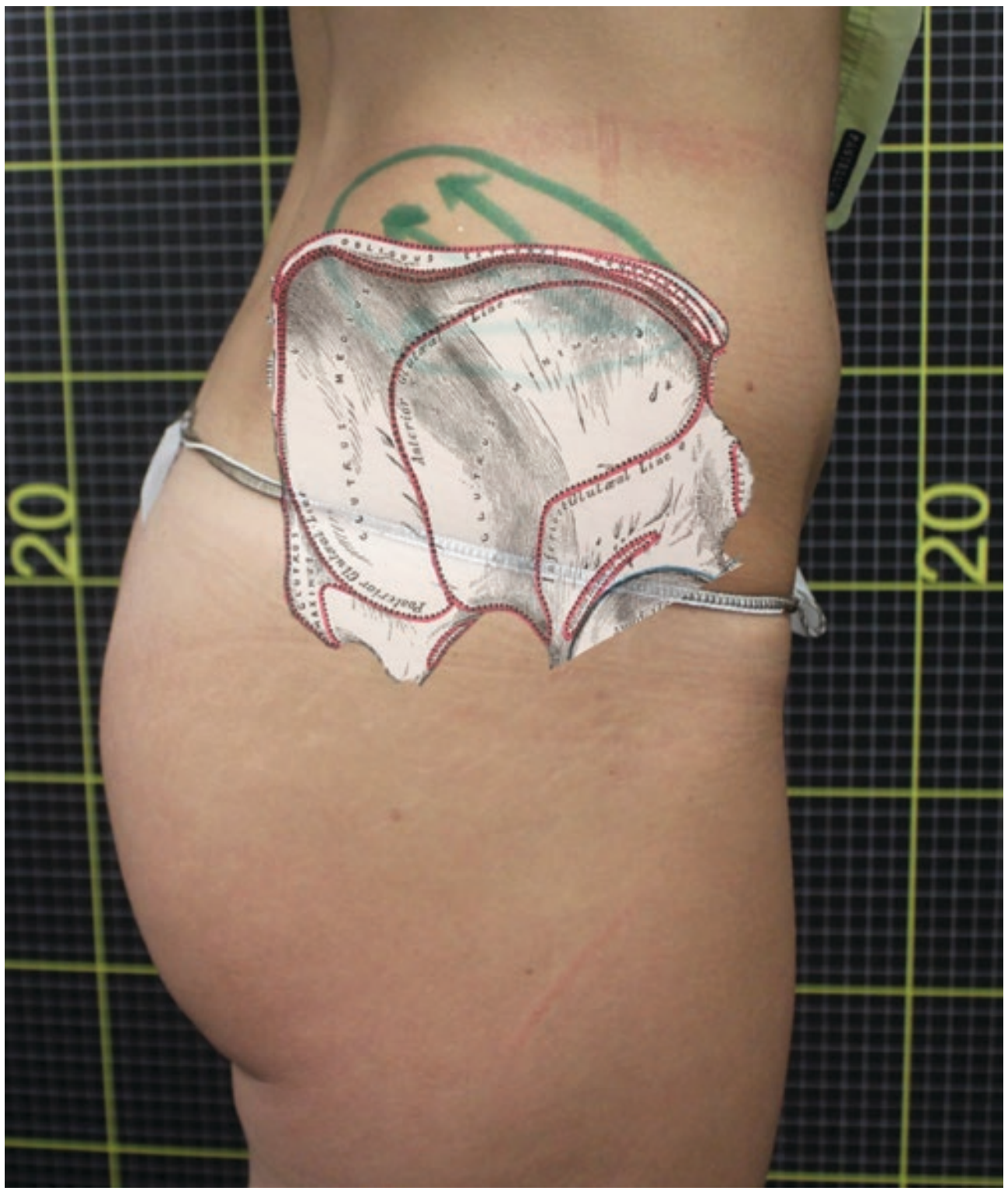

Fig. 3.8 Marking the harvesting area: the entry-point is signed in correspondence to the anterior superior iliac spine (ASIS). The flank fat pad is pinched and marked. (Published with kind permission of ©Mario Goisis 2018. All Rights Reserved)

Fig. 3.9 Locating the pad of fat on the flank before harvesting. (Published by kind permission of ©Mario Goisis 2018. All Rights Reserved)

saline solutions. The autoclavable cannula is produced also in a single-use version.

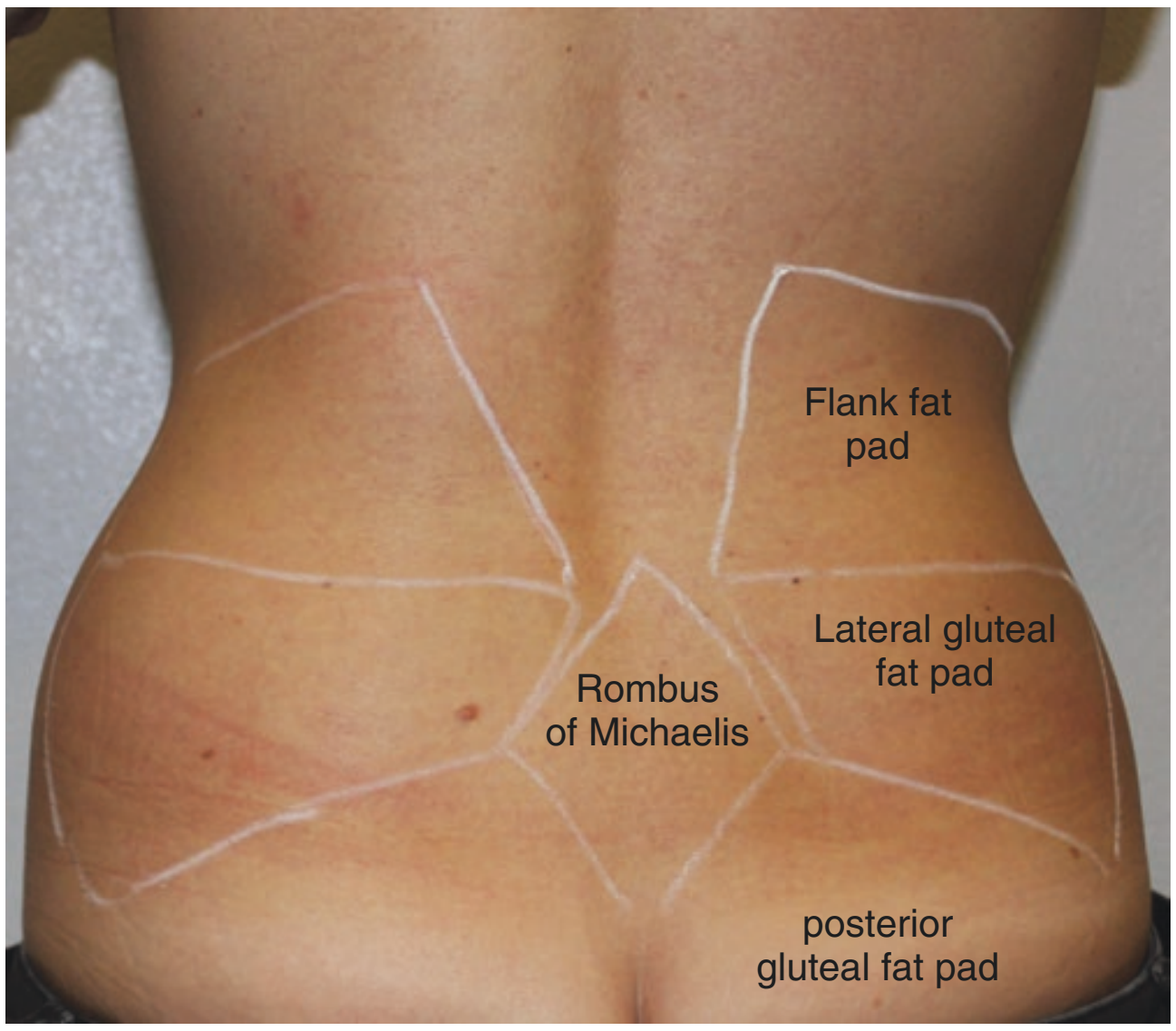

Fig. 3.10 Posterior view of areas from which fat may be harvested. (Published by kind permission of ©Mario Goisis 2018. All Rights Reserved)

Fig. 3.11 The instruments used for harvesting using the Microfat Box. (Published by kind permission of ©Mario Goisis 2018. All Rights Reserved)

Other necessary supplies are a chlorhexidine-alcohol solution (2% chlorhexidine gluconate and 70% isopropyl alcohol), sterile drapes or towels, ice packs, sterile 2 cm x 2 cm gauze squares, and an occlusive dressing cover.

When initially performing lipoaspiration, ultrasound guidance can be very useful, but once one's level of competence improves, it is not always needed. However, it should be included in the procedure when operating on thin patients. Ultrasound is a useful tool to determine the thickness of adipose tissue and the optimal site for harvesting. When using ultrasound, a sterile ultrasound transducer condom is required.